

Protocol for the Examination of Specimens From Patients With Carcinomas of the Thyroid Gland

Protocol applies to all carcinomas of the thyroid gland. Lymphomas, sarcomas, and metastases are not included.

Based on AJCC/UICC TNM, 7th edition

Protocol web posting date: January 2016

Authors

Raja R. Seethala, MD, FCAP*

Department of Pathology, University of Pittsburgh, Pittsburgh, PA

Sylvia L. Asa, MD, PhD, FCAP

Department of Pathology, University Health Network, Toronto, ON

Sally E. Carty, MD, FACS

Department of Surgery, Division of Endocrine Surgery, University of Pittsburgh, Pittsburgh, PA

Steven P. Hodak, MD

Department of Endocrinology, University of Pittsburgh, Pittsburgh, PA

Jonathan B. McHugh, MD, FCAP

Department of Pathology, University of Michigan, Ann Arbor, MI

Mary S. Richardson, MD, DDS, FCAP

Department of Pathology, Medical University of South Carolina, Charleston, SC

Jatin Shah, MD, FACS

Department of Head and Neck Service, Department of Surgery, Memorial Sloan-Kettering Cancer Center, New York, NY

Lester D. R. Thompson, MD, FCAP

Department of Pathology, Southern California Permanente Medical Group, Woodland Hills, CA

Yuri E. Nikiforov, MD, PhD FCAP†

Department of Pathology, University of Pittsburgh, Pittsburgh, PA

For the Members of the Cancer Committee, College of American Pathologists

* Denotes primary author. † Denotes senior author. All other contributing authors are listed alphabetically.

Previous contributors: Ronald Ghossein, MD, Leon Barnes, MD, Louis B. Harrison, MD, Clara Heffess, MD, Jennifer Hunt, MD, Bruce Wenig, MD

© 2016 College of American Pathologists (CAP). All rights reserved.

The College does not permit reproduction of any substantial portion of these protocols without its written authorization. The College hereby authorizes use of these protocols by physicians and other health care providers in reporting on surgical specimens, in teaching, and in carrying out medical research for nonprofit purposes. This authorization does not extend to reproduction or other use of any substantial portion of these protocols for commercial purposes without the written consent of the College.

The CAP also authorizes physicians and other health care practitioners to make modified versions of the Protocols solely for their individual use in reporting on surgical specimens for individual patients, teaching, and carrying out medical research for nonprofit purposes.

The CAP further authorizes the following uses by physicians and other health care practitioners, in reporting on surgical specimens for individual patients, in teaching, and in carrying out medical research for non-profit purposes: (1) **Dictation** from the original or modified protocols for the purposes of creating a text-based patient record on paper, or in a word processing document; (2) **Copying** from the original or modified protocols into a text-based patient record on paper, or in a word processing document; (3) The use of a **computerized system** for items (1) and (2), provided that the Protocol data is stored intact as a single text-based document, and is not stored as multiple discrete data fields.

Other than uses (1), (2), and (3) above, the CAP does not authorize any use of the protocols in electronic medical records systems, pathology informatics systems, cancer registry computer systems, computerized databases, mappings between coding works, or any computerized system without a written license from the CAP.

Any public dissemination of the original or modified protocols is prohibited without a written license from the CAP.

The College of American Pathologists offers these protocols to assist pathologists in providing clinically useful and relevant information when reporting results of surgical specimen examinations of surgical specimens. The College regards the reporting elements in the “Surgical Pathology Cancer Case Summary” portion of the protocols as essential elements of the pathology report. However, the manner in which these elements are reported is at the discretion of each specific pathologist, taking into account clinician preferences, institutional policies, and individual practice.

The College developed these protocols as an educational tool to assist pathologists in the useful reporting of relevant information. It did not issue the protocols for use in litigation, reimbursement, or other contexts. Nevertheless, the College recognizes that the protocols might be used by hospitals, attorneys, payers, and others. Indeed, effective January 1, 2004, the Commission on Cancer of the American College of Surgeons mandated the use of the data elements of the protocols as part of its Cancer Program Standards for Approved Cancer Programs. Therefore, it becomes even more important for pathologists to familiarize themselves with these documents. At the same time, the College cautions that use of the protocols other than for their intended educational purpose may involve additional considerations that are beyond the scope of this document.

The inclusion of a product name or service in a CAP publication should not be construed as an endorsement of such product or service, nor is failure to include the name of a product or service to be construed as disapproval.

CAP Thyroid Gland Protocol Revision History

Version Code

The definition of version control and an explanation of version codes can be found at www.cap.org (search: cancer protocol terms).

Version: Thyroid 3.2.0.0

Summary of Changes

The following changes have been made since the August 2014 release.

The following data elements were modified:

- Lymph Node Sampling
- Extranodal Extension (changed to required only if lymph nodes present in specimen)

The following data elements were deleted:

- Specimen Size
- Specimen Weight
- Ancillary Studies

Surgical Pathology Cancer Case Summary

Protocol web posting date: January 2016

THYROID GLAND: Resection

Select a single response unless otherwise indicated.

Procedure (select all that apply) (Note A)

- Reoperative resection (ie, completion thyroidectomy)
- Partial excision (anything less than a lobectomy, including substernal excision)
 - Right
 - Left
 - Other (specify): _____
- Lobectomy
 - Right
 - Left
- Lobectomy with isthmusectomy (hemithyroidectomy)
 - Right
 - Left
- Subtotal or near total thyroidectomy (lobectomy with isthmusectomy and partial contralateral lobectomy)
 - Right lobe with partial left lobectomy
 - Left lobe with partial right lobectomy
- Total thyroidectomy

Lymph Node Sampling (select all that apply) (required only if applicable)

- Focused or single lymph node resection
- Central compartment dissection (level VI - pretracheal, paratracheal and prelaryngeal/Delphian, perithyroidal)
- Lateral neck dissection (level I-V)
 - Right
 - Left
- Superior mediastinal lymph nodes (level VII)
- Other (specify): _____

Tumor Laterality (select all that apply) (Note B)

- Right lobe
- Left lobe
- Isthmus
- Pyramidal lobe
- Other (specify): _____

Tumor Focality (Note B)

- Unifocal
- Multifocal

Tumor Size (Note C)

- Greatest dimension: ___ cm
 + Additional dimensions: ___ x ___ cm
 Cannot be determined (explain): _____

+ Data elements preceded by this symbol are not required. However, these elements may be clinically important but are not yet validated or regularly used in patient management.

Histologic Type (select all that apply) (Notes D and E)

- Papillary carcinoma
 - Common significant variants (Note F) (required only if applicable):
 - Classic (usual, conventional)
 - Follicular variant, encapsulated/well demarcated
 - Tumor capsular invasion:
 - Yes
 - No
 - Follicular variant, infiltrative
 - Tall cell variant
 - Cribriform-morular variant
 - Diffuse sclerosing variant
 - Other variant (specify) (Note F): _____
- Follicular carcinoma (Note G)
 - Variant (required only if applicable):
 - Oncocytic (Hürthle cell)
 - Other variant (specify): _____
 - Extent of tumor invasion:
 - Minimally invasive
 - Widely invasive
- Poorly differentiated thyroid carcinoma (Note H)
- Undifferentiated (anaplastic) carcinoma (Note H)
 - Focal or minor component without extrathyroidal extension
 - Major component
- Medullary carcinoma
- Other (specify): _____
- Carcinoma, type cannot be determined

Margins (Note I)

- Cannot be assessed
- Margins uninvolved by carcinoma
 - + Distance of invasive carcinoma to closest margin: ___ mm
- Margin(s) involved by carcinoma
 - + Site(s) of involvement: _____

Angioinvasion (vascular invasion) (select all that apply) (Note J)

- Cannot be determined
- Not identified
- Present
 - + Extent:
 - + Focal (less than 4 vessels)
 - + Extensive (4 or more vessels)

Lymphatic Invasion (Note J)

- Cannot be determined
- Not identified
- Present

+ Perineural Invasion

- + Cannot be determined
- + Not identified
- + Present

Extrathyroidal Extension (select all that apply) (Note K)

- Cannot be determined
 Not identified
 Present
 + Extent:
 + Minimal
 + Extensive

Pathologic Staging (pTNM) (Notes L through P)TNM Descriptors (required only if applicable) (select all that apply)

- m (multiple primary tumors)
 r (recurrent)
 y (posttreatment)

Primary Tumor (pT)

- pTX: Cannot be assessed
 pT0: No evidence of primary tumor
 pT1: Tumor size 2 cm or less, limited to thyroid
 pT1a: Tumor 1 cm or less in greatest dimension limited to the thyroid
 pT1b: Tumor more than 1 cm but not more than 2 cm in greatest dimension, limited to the thyroid
 pT2: Tumor more than 2 cm, but not more than 4 cm, limited to thyroid
 pT3: Tumor more than 4 cm limited to thyroid or any tumor with minimal extrathyroid extension (eg, extension to sternothyroid muscle or perithyroidal soft tissues)
 pT4a: Moderately advanced disease. Tumor of any size extending beyond the thyroid capsule to invade subcutaneous soft tissues, larynx, trachea, esophagus or recurrent laryngeal nerve
 pT4b: Very advanced disease. Tumor invades prevertebral fascia or encases carotid artery or mediastinal vessels

Note: There is no category of carcinoma in situ (pTis) relative to carcinomas of thyroid gland.

Undifferentiated (Anaplastic) Carcinoma

- pT4a: Intrathyroidal undifferentiated (anaplastic) carcinoma
 pT4b: Undifferentiated carcinoma (anaplastic) with gross extrathyroid extension

Regional Lymph Nodes (pN)[#] (Notes M and N)

- pNX: Regional lymph nodes cannot be assessed
 pN0: No regional lymph node metastasis
 pN1a: Metastasis to level VI (pretracheal, paratracheal and prelaryngeal/Delphian, perithyroidal) lymph nodes
 pN1b: Metastasis to unilateral, bilateral or contralateral cervical (levels I, II, III, IV, V) or retropharyngeal or superior mediastinal lymph nodes (level VII)

Specify: Number examined: ____
 Number involved: ____
 Size (greatest dimension) of the largest metastatic focus in the lymph node: ____
 (required only if applicable)

Lymph nodes with "psammoma bodies only"^{##}

[#] Superior mediastinal lymph nodes are considered regional lymph nodes (level VII). Midline nodes are considered ipsilateral nodes.

^{##} As there are currently no guidelines for pN staging with psammoma bodies only, these cases are best classified as pNX.

Extranodal Extension (required only if positive lymph nodes present in specimen) (Notes M and N)

- Not identified
 Present
 Cannot be determined

Distant Metastasis (pM) (required only if confirmed pathologically in this case)

___ pM1: Distant metastasis
Specify site(s), if known: _____

+ Additional Pathologic Findings (select all that apply)

- + ___ Adenoma
- + ___ Adenomatoid nodule(s) or nodular follicular disease (eg, nodular hyperplasia, goitrous thyroid)
- + ___ Diffuse hyperplasia (Graves disease)
- + ___ Thyroiditis (specify type): _____
- + ___ Parathyroid gland(s):
 - + ___ Not present
 - + ___ Present (specify number and location): _____
 - + ___ Within normal limits
 - + ___ Hypercellular
 - + ___ Other (specify): _____
- + ___ C-cell hyperplasia
- + ___ None identified
- + ___ Other (specify): _____

+ Ancillary Studies

Note: For reporting molecular testing and other cancer biomarker testing results, the CAP Thyroid Biomarker Template should be used. Pending biomarker studies should be listed in the Comments section of this report.

+ Clinical History (select all that apply)

- + ___ Radiation exposure:
 - + ___ Yes (specify type): _____
 - + ___ No
 - + ___ Unknown
- + ___ Family history
- + ___ Other (specify): _____

+ Comment(s)

Explanatory Notes

Scope of Guidelines

The reporting of thyroid cancer is facilitated by the provision of a case summary illustrating the features required for comprehensive patient care. However, there are many cases in which the individual practicalities of applying such a case summary may not be straightforward. Common examples include finding the prescribed number of lymph nodes, trying to determine the compartments of the radical neck dissection, and determining if isolated tumor cells in a lymph node represent metastatic disease. Case summaries have evolved to include clinical, radiographic, morphologic, immunohistochemical, and molecular results in an effort to guide clinical management. This case summary tries to remain simple while still incorporating important pathologic features as proposed by the American Joint Committee on Cancer (AJCC) Cancer Staging Manual,¹ the World Health Organization Classification of Tumours,² the TNM classification, the American College of Surgeons Commission on Cancer, and the International Union Against Cancer (UICC).³ This protocol is to be used as a guide and resource, an adjunct to diagnosing and managing cancers of the thyroid gland in a standardized manner. It should not be used as a substitute for dissection or grossing techniques and does not give histologic parameters to reach the diagnosis. Subjectivity is always a factor, and elements listed are not meant to be arbitrary but are meant to provide uniformity of reporting across all the disciplines that use the information. It is a foundation of practical information that will help to meet the requirements of daily practice to benefit both clinicians and patients alike.

A. Anatomical Sites of the Thyroid Gland (Figure 1)

The thyroid gland ordinarily is composed of a right and a left lobe lying adjacent and lateral to the upper trachea and esophagus. An isthmus connects the 2 lobes, and in some cases a pyramidal lobe is present extending cephalad anterior to the thyroid cartilage. Typically, surgical management of thyroid tumors consists of either a lobe with isthmusectomy (sometimes called *hemithyroidectomy*) or total thyroidectomy. Cases with lobectomy followed by completion thyroidectomy in the same operative procedure should be classified as total thyroidectomies. Other procedures include subtotal thyroidectomy and level VI central node dissection.

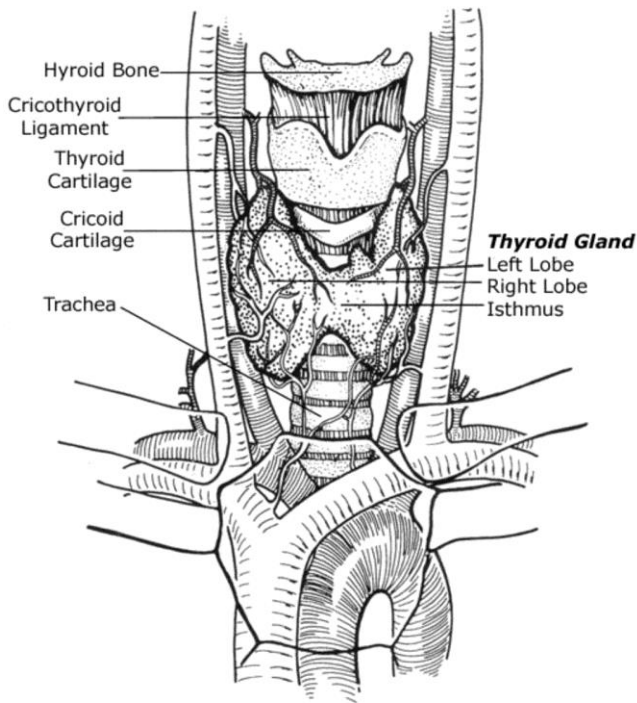


Figure 1. Anatomy of the thyroid gland and adjacent structures. From Kini SR. *Thyroid Cytopathology: An Atlas and Text*. Philadelphia, PA: Lippincott Williams & Wilkins; 2008. Modified with permission.

B. Tumor Site

The thyroid may give rise to multiple foci of carcinoma in the same gland, designated as per AJCC guidelines with the descriptor “(m).” This protocol is applicable to the dominant excised tumor. The dominant tumor can be defined as the most aggressive tumor, specifically the tumor that imparts the highest stage and dictates patient management. As such, it is often but not necessarily the largest tumor. In cases of multiple lesions, the tumor characteristics of a second or rarely third focus may be relevant and contribute to the patient management, particularly if they are of a different histologic type (ie, tumor 1 is papillary carcinoma, and tumor 2 is medullary carcinoma). A second synoptic report can be generated for these instances. The features of additional foci that do not necessarily alter management can be detailed under the section on Additional Pathologic Findings.

C. Tumor Size

Tumor size has a significant impact on prognosis and is a component of TNM staging. Papillary carcinomas measuring less than 1 cm are associated with an excellent prognosis, while tumors measuring over 4 cm are associated with a worse prognosis. For follicular carcinomas, tumor size over 3.5 cm is associated with a worse prognosis.⁴ For medullary carcinomas, size is a staging component, though a recent epidemiologic survey shows that even small tumors (microcarcinomas <1.0 cm) have a 20% rate of regional spread and a 5% distant metastatic rate.⁵

D. Histologic Type

The histologic classification recommended below in notes F through H is modified from the World Health Organization (WHO) published recommendations with a few important alterations based on subsequently published studies.² This protocol applies only to carcinomas and does not apply to lymphomas, sarcomas, or metastatic tumors to the thyroid gland.

WHO Classification of Carcinoma of the Thyroid

Papillary carcinoma

Variants (in alphabetical order):

- Classic (usual)
- Clear cell variant
- Columnar cell variant
- Cribriform-morular variant
- Diffuse sclerosing variant
- Follicular variant
- Macrofollicular variant
- Microcarcinoma (occult, latent, small, microtumor)
- Oncocytic or oxyphilic variant (follicular variant, nonfollicular variant)
- Solid variant
- Tall cell variant
- Warthin-like variant

Follicular carcinoma

Variants:

- Clear cell variant
- Oncocytic (Hürthle cell) variant

Poorly differentiated thyroid carcinomas including insular carcinoma

Medullary carcinoma

Undifferentiated (anaplastic) carcinoma

Carcinoma, type cannot be determined

E. Histologic Grade

While AJCC includes a generic 4-tiered scheme for thyroid cancers as with other cancers, application of this to the current classification of thyroid cancers is difficult and not particularly relevant, as there is no grading system beyond what is implied by each specific histologic variant.

F. Papillary Carcinoma

Papillary carcinoma is the most common carcinoma type and consists of numerous named variants, though only a few of these currently have sufficient evidence to be considered clinically and biologically relevant. Thus effort should be made to flag or document the following variants when present:

- Classic (usual, conventional)
- Follicular variant, encapsulated/well demarcated
- Follicular variant, infiltrative
- Tall cell variant
- Cribriform-morular variant
- Diffuse sclerosing variant

Classic (usual, conventional) papillary carcinoma is the most common and “default” variant of papillary carcinoma. Tall cell variant of papillary carcinoma is a more aggressive variant that has a higher prevalence of *BRAF* mutations (see also note Q) and is more frequently refractory to radioactive iodine therapy.⁶⁻⁸ The cribriform morular variant is a biologically distinct variant characterized by *APC* or beta catenin mutations, and shows an association with familial adenomatous polyposis coli, in some cases preceding recognition of colon polyps or other extracolonic manifestations.⁹ Diffuse sclerosing variant is a locoregionally aggressive variant with a high rate of nodal metastasis and locoregional recurrence, though overall survival when corrected for other high-risk parameters is not entirely clear. Nonetheless, this variant appears to necessitate more aggressive initial surgical management including extent of node dissection.¹⁰

Follicular variant of papillary carcinoma is important to document because it has recently been substratified based on outcome into encapsulated/well demarcated and unencapsulated/infiltrative follicular variants. Unencapsulated follicular variants have a behavior similar to classic papillary carcinoma, particularly in terms of propensity for nodal metastasis, while the behavior of encapsulated follicular variant is more similar to follicular adenoma or follicular carcinoma, if the tumor shows capsular invasion.^{11,12}

Other variants that may have prognostic and therapeutic value but are rare and not well validated include:

- Clear cell
- Columnar cell
- Hobnail cell*
- Macrofollicular
- Oncocytic or oxyphilic
- Solid
- Warthin-like

*Not part of the WHO classification as it had been described subsequent to this.

Reporting of these is optional but recommended.

Papillary microcarcinomas (also historically referred to as papillary microtumor, occult, latent or small papillary carcinoma) are not technically a specific variant but refer to papillary carcinomas that are found incidentally measuring 1 cm or less.² In spite of their rather common identification in thyroid gland resections^{13,14} and apparent indolent biologic behavior, it is the recommendation to issue a protocol for all cases in which papillary thyroid carcinoma is found, including subcentimeter carcinomas, whether incidentally found in a thyroid gland removed for other reasons (eg, multinodular goiter), discovered clinically (palpable, visible nodule), and/or discovered by imaging. Given the more sophisticated diagnostic (eg, imaging) modalities currently available, small (ie, less than 1 cm) lesions are being identified and resected. In an effort to have these papillary microcarcinomas reported and documented in tumor registries, thereby providing for long-term follow-up and better determination of their biologic nature, it is recommended that they should also be reported following this CAP thyroid protocol. More recently, certain histologic features have been shown to correlate with nodal metastasis in papillary microcarcinomas. A combined histologic-molecular scoring scheme has been proposed for microcarcinomas based on *BRAF* mutation status, subcapsular location, peri- and intratumoral fibrosis, and multifocality. This is not yet validated, but documentations of the aforementioned morphologic parameters (with or without mutational status) may be useful in management.¹⁵

G. Follicular Carcinoma

Follicular carcinoma is a well-differentiated carcinoma type defined by invasiveness in the absence of diagnostic nuclear features of papillary thyroid carcinoma. The diagnosis of follicular carcinoma and its distinction from follicular adenoma primarily depends on the identification of invasion of the tumor capsule and/or vascular spaces (see also note I).

There are a few variants that are recognized in the WHO classification. The most commonly named variant is:
Oncocytic variant (Hürthle cell carcinoma)

Despite the current designation as a variant of follicular carcinoma, historically oncocytic carcinoma was considered a distinct entity. Even now the debate continues as to whether this tumor is sufficiently biologically distinct as to warrant categorization as a separate entity. This variant is often more aggressive and radioactive iodine resistant, and unlike follicular carcinoma, this variant can metastasize to lymph nodes. However, when controlled for stage and extent of invasion, this difference is diminished.¹⁶

Other proposed subtypes that are rare and of uncertain significance include:

- Clear cell variant
- Mucinous variant*
- Follicular carcinoma with signet-ring cells*

* Not part of the WHO classification.

Criteria for Capsular Invasion

While conceptually simple, there is no consensus as to the definition of capsular invasion. Some authorities require complete transgression of the capsule, while other authorities do not require complete transgression of the capsule. Figure 2⁴ depicts the various histologic appearances for the presence or absence of capsular invasion. While a number of the illustrated representations of capsular invasion would be accepted by all pathologists (eg, C, D, E, H), other depictions listed as “Not yet” (eg, F, G, I) may be acceptable to some pathologists as representing capsular invasion. The impact of previous biopsy may confound the interpretation of capsular invasion and must be considered.




Figure 2. Capsular invasion (CI). Schematic drawing for the interpretation of the presence or absence of CI. The diagram depicts a follicular neoplasm (orange) surrounded by a fibrous capsule (green). A. Bosselation on the inner aspect of the capsule does not represent CI. B. Sharp tumor bud invades into but not through the capsule suggesting invasion requiring deeper sections to exclude. C. Tumor totally transgresses the capsule invading beyond the outer contour of the capsule qualifying as CI. D. Tumor clothed by thin (probably new) fibrous capsule but already extending beyond an imaginary (dotted)

line drawn through the outer contour of the capsule qualifying as CI. E. Satellite tumor nodule with similar features (architecture, cytomorphology) to the main tumor lying outside the capsule qualifying as CI. F. Follicles aligned perpendicular to the capsule suggesting invasion requiring deeper sections to exclude. G. Follicles aligned parallel to the capsule do not represent CI. H. Mushroom-shaped tumor with total transgression of the capsule qualifies as CI. I. Mushroom-shaped tumor within but not through the capsule suggests invasion requiring deeper sections to exclude invasion. J. Neoplastic follicles in the fibrous capsule with a degenerated appearance accompanied by lymphocytes and siderophages does not represent CI but rather capsular rupture related to prior fine-needle aspiration.

From Fletcher CDM, ed. *Diagnostic Histopathology of Tumours*. 3rd ed. Edinburgh: Churchill Livingstone Elsevier; 2007. Modified with permission. © Elsevier.

The criteria defining *minimally invasive* follicular carcinoma are controversial and still evolving. The WHO classification system allows for this term to encompass encapsulated lesions with capsular and/or small-caliber sized angioinvasion, even if angioinvasion is extensive.

However, it is apparent in the literature that even within this group there is a survival difference between tumors with only capsular invasion (so called “true minimally invasive” follicular carcinomas) and those that are angioinvasive, with the latter being more aggressive. It is thus appropriate to further stratify minimally invasive tumors into these subcategories.^{16,17}

Widely invasive follicular carcinomas have similarly nebulous definition and consist of those tumors with grossly apparent invasion of thyroid and/or soft tissue (ie, extrathyroidal invasion).² The term is usually assigned to tumors with loss of encapsulation and multiple fronts of tumor invasion radiating from the epicenter of the tumor. These tumors are typically accompanied by other markers of aggressiveness such as extrathyroidal extension and extensive vascular invasion.

H. Poorly Differentiated and Undifferentiated (Anaplastic) Carcinoma

While the majority of thyroid cancers are well differentiated, a subset are poorly differentiated (historically known as insular, or trabecular, carcinoma) or undifferentiated (anaplastic). These tumor types represent progression to a more aggressive phenotype and are often seen with co-existent or antecedent well-differentiated carcinoma. While detailed histomorphologic review is beyond the scope of this protocol, salient features of both tumor types are listed below.

Briefly, poorly differentiated carcinomas are tumors that display a solid, trabecular, and/or insular growth pattern, and show one or more of the following: greater than 3 mitoses per 10 high-power fields, necrosis, and nuclear convolution (without other features seen in papillary carcinoma).¹⁸ As noted above, poorly differentiated thyroid carcinoma may be seen as a component of well-differentiated carcinoma, and as little as 10% of a poorly differentiated component is sufficient to confer an aggressive biologic behavior.¹⁹ On the other hand, encapsulated tumors appear to have a more favorable prognosis than unencapsulated tumors, particularly if they show no capsular or vascular invasion with adequate sampling.^{20,21}

Undifferentiated carcinoma represents the most extreme form of tumor progression and consists of a high-grade malignancy with spindled, pleomorphic, squamoid, or even rhabdoid morphology.²² Undifferentiated carcinoma is almost invariably rapidly lethal. The few exceptions are noteworthy as they mainly consist of well-differentiated tumor with only focal anaplastic transformation.²²⁻²⁴ These tumors are treatable surgically and will have a more favorable prognosis than a predominantly anaplastic carcinoma. Thus, tumors with only focal anaplastic areas and no extrathyroidal extension should be delineated from the more common and overtly anaplastic tumors. The maximum percentage of tumor that is allowable by the term *focal* in this context is unclear at this point, however, and will require judgment on a case-by-case basis.

I. Margins

By convention, margin status is a required data element in association with thyroid cancers. The “margin” is defined as the surface of the thyroid specimen, usually the outer aspect of the thyroid gland and/or inked edge of the specimen. The evaluation of the relationship of tumor to the inked edge of the tissue represents determination of margin status. It should be noted that the thyroid “capsule” is not an anatomically defined structure. Evidence has shown that microscopically the capsule is focally incomplete or absent in a majority of thyroid glands evaluated at autopsy.¹³ Further, unlike hollow organs such as the gastrointestinal tract where there is continuity of

the entire viscera such that a real surgical and pathologic margin exists, the same does not hold true for the thyroid gland such that tumor at the margin (ie, capsule and/or ink) does not correlate to incomplete excision. Few published studies have addressed the influence of margin status and patient outcome. Most surgeons, endocrinologists, and nuclear medicine specialists request information on margin status. While this makes intuitive sense, and it is recommended that a positive margin be mentioned in the final pathology report, meticulous studies on the effect of positive margins and outcome in large series of patients with long-term follow-up are lacking. Indeed, there is no data to date on the prognostic value of close margins as an independent or co-variable.

J. Angioinvasion (Vascular Invasion) and Lymphatic Invasion

Angiolymphatic invasion is an important parameter for both papillary and follicular carcinomas. Given the preferential spread of papillary carcinoma via lymphatics and follicular carcinoma via hematogenous routes, the vessels invaded by papillary carcinoma are usually lymphatic spaces and those in follicular carcinoma are usually blood vessels. However, papillary carcinomas can involve vascular spaces, as indicated by occasional hematogenous spread. Thus, the distinction between vascular and lymphatic invasion may be helpful in that the former is a predictor of a more aggressive pattern of spread.

Criteria for Angioinvasion

As noted above, papillary thyroid carcinomas tend to spread via lymphatics. In addition to tumor deposits within lymphatic spaces, this form of spread may manifest as psammoma bodies alone within these spaces, which are the equivalent of lymphatic invasion for reporting purposes.

For encapsulated follicular carcinomas, criteria are designed to identify venous vascular invasion, as this is the typical means of spread for these tumors. Vascular invasion can be a diagnostic criterion for follicular carcinoma and appears to correlate with poor outcome. As with capsular invasion, vascular invasion, though conceptually straightforward, is controversial and challenging.

For vascular invasion, the blood vessels should be located outside the tumor, within the capsule, or outside the capsule.²⁵ The involved spaces should include capsular or extracapsular vessels. While angioinvasion of a venous caliber space is fairly easily recognized, occasionally separating capillary sized vascular spaces from lymphatics may be difficult. Morphologically smaller vascular spaces will still have red blood cells within. In challenging cases, markers selective for vascular and lymphatic endothelium, such as CD31 and podoplanin (D2-40) respectively, may be useful.²⁶ Figure 3 depicts the various histologic appearances of vascular invasion.⁴ The minimal requirements for clinically meaningful vascular invasion are currently a point of controversy. Historically, the presence of endothelialized tumor alone has been the minimal criterion to identify vascular space invasion, a finding supported in the literature.²⁵ More recently, however, one group has raised the caveat that tumor cells within vascular lumina unassociated with thrombus, and tumor cells underlying intact endothelium could represent “pseudoinvasion” given the fenestrated endothelial network of endocrine organs.²⁶ Using more rigorous criteria, namely invasion of tumor cells through a vessel wall as well as thrombus formation in association with tumor, this group demonstrated that over one-third of tumors that fulfilled these criteria had distant metastases.²⁶ These rigid criteria are also highly predictive of aggressive disease in medullary thyroid carcinoma.²⁷

While these more rigid criteria require validation from additional studies, they set the framework for the minimal criteria for unequivocal and meaningful vascular invasion, to reiterate: invasion of tumor through a vessel wall accompanied by fibrin thrombus. It is acknowledged that the risk of metastasis when these criteria are not fulfilled by a focus in vessels is not entirely absent.²⁸

Additionally, some investigators have suggested that the number of foci of vascular invasion has prognostic impact as well.²⁹⁻³¹ In some studies, encapsulated follicular carcinoma, oncocytic variant with 4 or more foci of vascular invasion, has a significant recurrence rate (47%) even if the foci of angioinvasion are microscopic.³⁰ On the other hand, another study showed that follicular oncocytic (Hürthle cell) carcinomas with a total of 2 foci of capsular/vascular invasion did not recur after a long follow up.³¹ Moreover, in a series of 4000 thyroid carcinomas of follicular epithelial origin, angioinvasive differentiated thyroid carcinomas that developed distant metastases revealed predominantly a single focus of angioinvasion, and there were no more than 2 foci of vascular invasion.²⁶ Thus, the use of appropriate criteria seems to be more critical than the number of involved vessels.²⁶

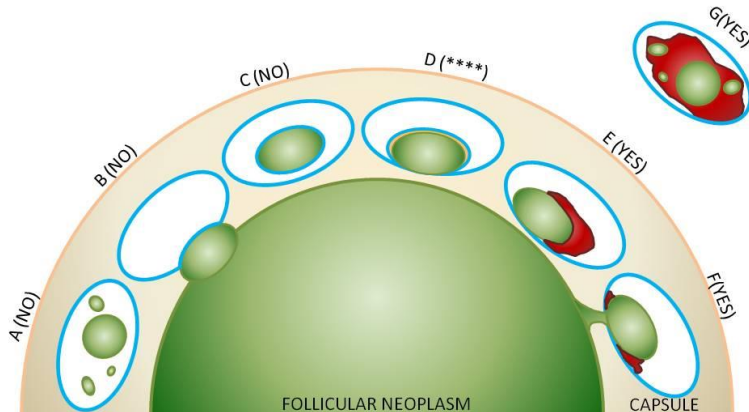


Figure 3. Vascular invasion (VI): Schematic drawing for the interpretation of the presence or absence of significant VI. The diagram depicts a follicular neoplasm (green) surrounded by a fibrous capsule (tan). The driving concepts behind significant VI are penetration through the vessel wall and a reaction to the vascular deposit, namely thrombus formation, which may range from subtle and fibrinoid in nature to large and heavily organized.²⁶

A through C represent scenarios where tumor in vessels are not counted as VI. A. Free-floating irregular tumor fragments often result from artifactual displacement. B. Tumor bulging and indenting the vessel wall does not count as VI. C. Endothelialized tumor floating in an intracapsular vessel may result from tangential sectioning of tumor bulging into a vessel, often at a branch or bifurcation. These findings can however prompt deeper levels (at least by 3) to exclude definitive VI (see E through G).

**** D represents a common but contentious scenario among experts, in light of these new proposed criteria for significant VI. This endothelialized tumor deposit is juxtaposed to the vessel wall. As this is somewhat similar to C, and there is no obvious thrombus, technically this would not count as significant VI. One counterargument is that the endothelialized appearance represents “organization” of a tumor thrombus and is thus still significant. While deeper levels may help, this scenario may still be considered a “judgment call” based on current level of evidence.

E through G represent unequivocal VI. E. Tumor is juxtaposed to vessel wall and is associated with a thrombus. F. Tumor penetrating vessel wall also demonstrating thrombus formation at its neck. G. Tumor fragments in intermingled with an organized thrombus and adherent to vessel wall.

Note: While there is no standard definition of “deeper levels,” generally, each level is at a certain interval (ie, 3 serial sections deeper or 15-micron intervals) below the original H&E rather than an immediate serial section.

Original concept for schematic from Fletcher CDM, ed. *Diagnostic Histopathology of Tumours*. 3rd ed. Edinburgh; Churchill Livingstone Elsevier; 2007. Modified with permission. © Elsevier.

K. Extrathyroidal Extension

Extrathyroidal extension refers to involvement of the perithyroidal tissues by a primary thyroid cancer. Since the thyroid gland does not have a well-defined capsule,³² the definition of extrathyroidal extension is problematic and subjective. On gross examination, the capsule may appear complete, but evidence has shown that microscopically the capsule is focally incomplete or absent in a majority of thyroid glands evaluated at autopsy.¹³ The perithyroidal tissues include sizable blood vessels as well as small peripheral nerves and are continuous with the pretracheal fascia.³³ Diagnostic findings for minimal extrathyroidal extension includes the presence of carcinoma extending into perithyroidal tissues, including infiltration of skeletal muscle, as well as around sizable vascular structures and nerves. If present, a desmoplastic response may be a helpful finding in the determination of extrathyroidal extension.³² Extension into adipose tissue is a problematic criterion if used alone, given the fact that adipose tissue can be found within the thyroid gland proper under normal conditions and also may be a component of a variety of thyroid lesions including carcinomas.^{25,34} Review of the surgeon’s operative report is encouraged as it may also describe evident capsular invasion, gross extrathyroidal extension, and/or unresected

tumor. Information on completeness of resection is also important in determining adjuvant therapy and surveillance regimen.³⁵

In contrast to minimal extrathyroidal extension, the histologic diagnosis of extensive extrathyroidal extension is rather straightforward and is usually established clinically by documentation of carcinoma well beyond the thyroid gland with direct invasion (ie, not metastasis) into one or more of the following structures:

- Subcutaneous soft tissues
- Adjacent viscera, including the larynx, trachea, and/or esophagus
- The recurrent laryngeal nerve, carotid artery, or mediastinal blood vessels

L. TNM and Stage Groupings

According to the American Joint Committee on Cancer (AJCC),¹ the TNM stage groupings for papillary and follicular carcinomas and variants thereof are stratified by age, including patients under 45 years of age and patients 45 years and older. Similar stratification is not used in the staging of medullary carcinomas or undifferentiated carcinoma. However, undifferentiated (anaplastic) carcinoma is always assigned stage IV. Tumor size and lymph node status are also considered in the TNM classification.

All categories may be subdivided: (a) solitary tumor, (b) multifocal tumor. With multifocal tumors, the largest one is used for classification. The multifocal designation may be used for tumors of different histologies (ie, a follicular and papillary carcinoma, not just multiple papillary carcinomas). The lymph nodes must be specifically identified to classify regional node involvement.

Primary Tumor (pT)

pTX	Cannot be assessed
pT0	No evidence of primary tumor
pT1	Tumor size 2 cm or less, limited to thyroid
pT1a	Tumor 1 cm or less in greatest dimension limited to the thyroid
pT1b	Tumor more than 1 cm but not more than 2 cm in greatest dimension, limited to the thyroid
pT2	Tumor more than 2 cm, but not more than 4 cm, limited to thyroid
pT3	Tumor more than 4 cm limited to thyroid or any tumor with minimal extrathyroid extension (eg, extension to sternothyroid muscle or perithyroid soft tissues)
pT4a	Moderately advanced disease. Tumor of any size extending beyond the thyroid capsule to invade subcutaneous soft tissues, larynx, trachea, esophagus or recurrent laryngeal nerve
pT4b	Very advanced disease. Tumor invades prevertebral fascia or encases carotid artery or mediastinal vessels

Note: There is no category of carcinoma in situ (pTis) relative to carcinomas of thyroid gland.

All undifferentiated (anaplastic) carcinomas are considered T4 tumors.

pT4a	Intrathyroidal undifferentiated (anaplastic) carcinoma
pT4b	Undifferentiated carcinoma (anaplastic) with gross extrathyroid extension

By AJCC/UICC convention, the designation “T” refers to a primary tumor that has not been previously treated. The symbol “p” refers to the pathologic classification of the TNM, as opposed to the clinical classification, and is based on gross and microscopic examination. pT entails a resection of the primary tumor or biopsy adequate to evaluate the highest pT category, pN entails removal of nodes adequate to validate lymph node metastasis, and pM implies microscopic examination of distant lesions. Clinical classification (cTNM) is usually carried out by the referring physician before treatment during initial evaluation of the patient or when pathologic classification is not possible.

Pathologic staging is usually performed after surgical resection of the primary tumor. Pathologic staging depends on pathologic documentation of the anatomic extent of disease, whether or not the primary tumor has been completely removed. If a biopsied tumor is not resected for any reason (eg, when technically unfeasible) and if the highest T and N categories or the M1 category of the tumor can be confirmed microscopically, the criteria for pathologic classification and staging have been satisfied without total removal of the primary cancer.

Regional Lymph Nodes (pN)

pNX	Regional lymph nodes cannot be assessed
pN0	No regional lymph node metastasis
pN1a	Metastasis to level VI (pretracheal, paratracheal and prelaryngeal/Delphian, perithyroidal) lymph nodes
pN1b	Metastases to unilateral, bilateral or contralateral cervical (levels I, II, III, IV, V) or retropharyngeal or superior mediastinal lymph nodes (level VII)

Distant Metastasis (pM)

pM0	No distant metastasis
pM1	Distant metastasis

Stage GroupingsPapillary or Follicular Carcinoma

	<i>Under 45 Years of Age</i>		
Stage I	Any T	Any N	M0
Stage II	Any T	Any N	M1

	<i>45 Years or Older</i>		
Stage I	T1	N0	M0
Stage II	T2	N0	M0
Stage III	T3	N0	M0
	T1	N1a	M0
	T2	N1a	M0
	T3	N1a	M0
Stage IVA	T4a	N0	M0
	T4a	N1a	M0
	T1	N1b	M0
	T2	N1b	M0
	T3	N1b	M0
	T4a	N1b	M0
Stage IVB	T4b	Any N	M0
Stage IVC	Any T	Any N	M1

Medullary Carcinoma (All Age Groups)

Stage I	T1	N0	M0
Stage II	T2	N0	M0
	T3	N0	M0
Stage III	T1	N1a	M0
	T2	N1a	M0
	T3	N1a	M0
Stage IVA	T4a	N0	M0
	T4a	N1a	M0
	T1	N1b	M0
	T2	N1b	M0
	T3	N1b	M0
	T4a	N1b	M0
Stage IVB	T4b	Any N	M0
Stage IVC	Any T	Any N	M1

Undifferentiated (Anaplastic) Carcinoma

All undifferentiated carcinomas are considered Stage IV

Stage IVA	T4a	Any N	M0
Stage IVB	T4b	Any N	M0
Stage IVC	Any T	Any N	M1

TNM Descriptors

For identification of special cases of TNM or pTNM classifications, the “m” suffix and “y,” “r,” and “a” prefixes are used. Although they do not affect the stage grouping, they indicate cases needing separate analysis.

The “m” suffix indicates the presence of multiple primary tumors in a single site and is recorded in parentheses: pT(m)NM.

The “y” prefix indicates those cases in which classification is performed during or following initial multimodality therapy (ie, neoadjuvant chemotherapy, radiation therapy, or both chemotherapy and radiation therapy). The cTNM or pTNM category is identified by a “y” prefix. The ycTNM or ypTNM categorizes the extent of tumor actually present at the time of that examination. The “y” categorization is not an estimate of tumor prior to multimodality therapy (ie, before initiation of neoadjuvant therapy).

The “r” prefix indicates a recurrent tumor when staged after a documented disease-free interval, and is identified by the “r” prefix: rTNM.

The “a” prefix designates the stage determined at autopsy: aTNM.

Additional Descriptors**Residual Tumor (R)**

In the thyroid gland, residual tumor may only be applicable to anaplastic carcinoma. Residual tumor is tumor remaining in a patient after therapy with curative intent (eg, surgical resection for cure) is categorized by a system known as R classification, shown below.

RX	Presence of residual tumor cannot be assessed
R0	No residual tumor
R1	Microscopic residual tumor
R2	Macroscopic residual tumor

For the surgeon, the R classification may be useful to indicate the known or assumed status of the completeness of a surgical excision. For the pathologist, the R classification is relevant to the status of the margins of a surgical resection specimen. That is, tumor involving the resection margin on pathologic examination may be assumed to correspond to residual tumor in the patient and may be classified as macroscopic or microscopic according to the findings at the specimen margin(s).

M. Classification of Neck Dissection

1. Radical neck dissection
2. Modified radical neck dissection, internal jugular vein and/or sternocleidomastoid muscle spared
3. Selective neck dissection (SND), as specified by the surgeon, with levels and sublevels designated (see Figure 3),^{36,37} such as:
 - a. Supraomohyoid neck dissection
 - b. Posterolateral neck dissection
 - c. Lateral neck dissection
 - d. Central compartment neck dissection
4. Superselective neck dissection, as specific by the surgeon
5. Extended radical neck dissection, as specified by the surgeon

N. Lymph Nodes

Regional lymph node spread from thyroid cancer is common but of less prognostic significance in patients with well-differentiated tumors (papillary) than in medullary cancers. The adverse prognostic influence of lymph node

metastasis in patients with differentiated carcinomas is observed only in the older age group.¹ In comparison to macrometastatic disease, micrometastases in thyroid cancer of follicular cell differentiation, using the generic definition of tumor deposits less than 2 mm in greatest dimension, are of even less clinical value. Based on a few studies to date, micrometastasis does not appear to confer an increased risk of locoregional recurrence as compared to node-negative patients and does not likely warrant more aggressive intervention.³⁸ The same holds true for isolated tumor cells and psammoma bodies only in lymph nodes. Reporting of “psammoma bodies only” in lymph nodes is not well defined. While indolent, they do indicate capacity for lymphatic spread. Thus, these should be documented, albeit in a separate field. For actual N-staging, in the absence of a strict requirement under AJCC staging, it is reasonable to classify these as pNX.³⁹ On the other end of the spectrum, larger size of lymph node metastases can confer a higher risk of locoregional recurrence, and the American Thyroid Association thus advocates reporting of the size of the largest metastatic focus.⁴⁰

The first echelon of nodal metastasis consists of the paralaryngeal, paratracheal, and prelaryngeal (Delphian) nodes adjacent to the thyroid gland in the central compartment of the neck, generally described as level VI.¹ Metastases secondarily involve the mid- and lower jugular, the supraclavicular, and (much less commonly) the upper deep jugular and spinal accessory lymph nodes.¹ Lymph node metastasis to submandibular and submental lymph nodes is very rare. Upper mediastinal (level VII) nodal spread occurs frequently both anteriorly and posteriorly. Retropharyngeal nodal metastasis may be seen, usually in the presence of extensive lateral cervical metastasis.¹ Bilateral nodal spread is common. The components of the N category are described as follows: first echelon (perithyroidal/central compartment/level VI), or N1a; and lateral cervical and/or superior mediastinal, or N1b. Commonly utilized surgical techniques for compartmental dissection often result in varying portions of the central compartment being resected en bloc with the thyroidectomy specimen, thus “perithyroidal” lymph nodes seen here are counted towards the N status of the patient (in addition to other parts formally labeled as central compartment or level VI).⁴¹ The lymph node metastasis should also be described according to the level of the neck that is involved. In comparison to metastatic head and neck squamous cell carcinoma, the risk for increased locoregional disease and distant metastasis in the presence of extranodal extension of thyroid cancer is not as widely validated, although several studies have shown an increase risk for distant metastases and death in the presence of extranodal extension.^{40,42,43} Therefore, as a recommendation, the pathologist should comment on the presence or absence of extranodal extension. Nodal metastases from medullary thyroid cancer carry a much more ominous prognosis, although they follow a similar pattern of spread.

For purposes of pathologic evaluation, lymph nodes are organized by levels as shown in Figure 4.⁴⁴

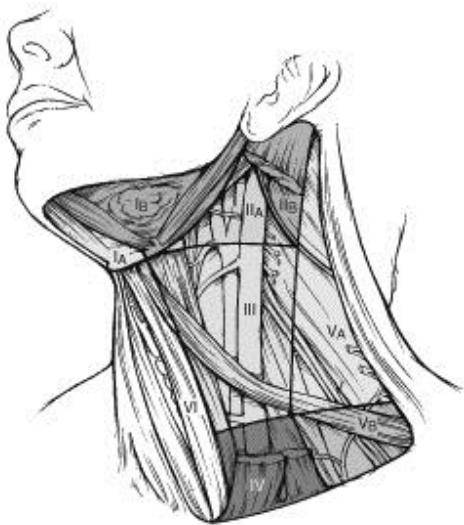

Figure 4. The 6 sublevels of the neck for describing the location of lymph nodes within levels I, II, and V. Level IA, submental group; level IB, submandibular group; level IIA, upper jugular nodes along the carotid sheath, including the subdigastric group; level IIB, upper jugular nodes in the submuscular recess; level VA, spinal accessory nodes; and level VB, the supraclavicular and transverse cervical nodes.

From Flint PW, et al, eds. *Cummings Otolaryngology: Head and Neck Surgery*. 5th ed. Philadelphia, PA; Saunders: 2010. Reproduced with permission. © Elsevier.

In order for pathologists to properly identify these nodes, they must be familiar with the terminology of the regional lymph node groups and with the relationships of those groups to the regional anatomy. Which lymph node groups surgeons submit for histopathologic evaluation depends on the type of neck dissection they perform. Therefore, surgeons must supply information on the types of neck dissections that they perform and on the details of the local anatomy in the specimens they submit for examination, or in other ways orient those specimens for pathologists.^{36,37}

If it is not possible to assess the levels of lymph nodes (for instance, when the anatomic landmarks in the excised specimens are not specified), then the lymph node levels may be estimated as follows: level II, upper third of internal jugular (IJ) vein or neck specimen; level III, middle third of IJ vein or neck specimen; level IV, lower third of IJ vein or neck specimen, all anterior to the sternocleidomastoid muscle.

Level I. Submental Group (Sublevel IA)

Lymph nodes within the triangular boundary of the anterior belly of the digastric muscles and the hyoid bone.

Submandibular Group (Sublevel IB)

Lymph nodes within the boundaries of the anterior and posterior bellies of the digastric muscle and the body of the mandible. The submandibular gland is included in the specimen when the lymph nodes within this triangle are removed.

Level II. Upper Jugular Group (Sublevels IIA and IIB)

Lymph nodes located around the upper third of the internal jugular vein and adjacent spinal accessory nerve extending from the level of the carotid bifurcation (surgical landmark) or hyoid bone (clinical landmark) to the skull base. The posterior boundary is the posterior border of the sternocleidomastoid muscle, and the anterior boundary is the lateral border of the sternohyoid muscle.

Level III. Middle Jugular Group

Lymph nodes located around the middle third of the internal jugular vein extending from the carotid bifurcation superiorly to the omohyoid muscle (surgical landmark), or cricothyroid notch (clinical landmark) inferiorly. The posterior boundary is the posterior border of the sternocleidomastoid muscle, and the anterior boundary is the lateral border of the sternohyoid muscle.

Level IV. Lower Jugular Group

Lymph nodes located around the lower third of the internal jugular vein extending from the omohyoid muscle superiorly to the clavicle inferiorly. The posterior boundary is the posterior border of the sternocleidomastoid muscle, and the anterior boundary is the lateral border of the sternohyoid muscle.

Level V. Posterior Triangle Group (Sublevels VA and VB)

This group comprises predominantly the lymph nodes located along the lower half of the spinal accessory nerve and the transverse cervical artery. The supraclavicular nodes are also included in this group. The posterior boundary of the posterior triangle is the anterior border of the trapezius muscle, the anterior boundary of the posterior triangle is the posterior border of the sternocleidomastoid muscle, and the inferior boundary of the posterior triangle is the clavicle.

Level VI. Anterior (Central) Compartment

Lymph nodes in this compartment include the pre- and paratracheal nodes, precricoid (Delphian) node, and the perithyroidal nodes, including the lymph nodes along the recurrent laryngeal nerve. The superior boundary is the hyoid bone, the inferior boundary is the suprasternal notch, the lateral boundaries are the common carotid arteries, and the posterior boundary by the prevertebral fascia.

Level VII. Superior Mediastinal Lymph Nodes

Metastases at level VII are considered regional lymph node metastases; all other mediastinal lymph node metastases are considered distant metastases.

Lymph node groups removed from areas not included in the above levels, eg, scalene, suboccipital, and retropharyngeal, should be identified and reported from all levels separately. Midline nodes are considered ipsilateral nodes.

O. Lymph Node Number

Histologic examination of a selective neck dissection specimen will ordinarily include 6 or more lymph nodes. Histologic examination of a radical or modified radical neck dissection specimen will ordinarily include 10 or more lymph nodes in the untreated neck.¹

P. Special Procedures for Lymph Nodes

At the current time, no additional special techniques should be used other than routine histology for the assessment of nodal metastases (ie, sentinel lymph node-type protocols are not advocated). However, confirmation by immunohistochemical staining, including thyroglobulin for papillary carcinoma and calcitonin and neuroendocrine markers (eg, chromogranins, synaptophysin, CD56) for medullary carcinoma, may be required.

References

1. Patel S, Shah JP. Head and neck sites. In: Edge SB, Carducci MA, Compton CA, eds. *AJCC Cancer Staging Manual*. 7th ed. New York, NY: Springer; 2009.
2. DeLellis RA, Lloyd RV, Heitz PU, Eng C, eds. *World Health Organization Classification of Tumours. Pathology and Genetics. Tumours of Endocrine Organs*. Lyon, France: IARC Press; 2004.
3. Gospodarowicz M, Wittekind C, Sobin LH, eds. *UICC TNM Classification of Malignant Tumours*. 7th ed. New York, NY: Wiley-Blackwell; 2010.
4. Chan JK. The thyroid gland. In: Fletcher CDM, ed. *Diagnostic Histopathology of Tumours*. Edinburgh: Churchill Livingstone Elsevier; 2007:1018.
5. Kazaure HS, Roman SA, Sosa JA. Medullary thyroid microcarcinoma: a population-level analysis of 310 patients. *Cancer*. 2012;118(3):620-627.
6. Morris LG, Shaha AR, Tuttle RM, Sikora AG, Ganly I. Tall-cell variant of papillary thyroid carcinoma: a matched-pair analysis of survival. *Thyroid*. 2010;20(2):153-158.
7. Nikiforov YE, Nikiforova MN. Molecular genetics and diagnosis of thyroid cancer. *Nat Rev Endocrinol*. 2011;7(10):569-580.
8. Rivera M, Ghossein RA, Schoder H, Gomez D, Larson SM, Tuttle RM. Histopathologic characterization of radioactive iodine-refractory fluorodeoxyglucose-positron emission tomography-positive thyroid carcinoma. *Cancer*. 2008;113(1):48-56.
9. Cameselle-Teijeiro J, Chan JK. Cribriform-morular variant of papillary carcinoma: a distinctive variant representing the sporadic counterpart of familial adenomatous polyposis-associated thyroid carcinoma? *Mod Pathol*. 1999;12(4):400-411.
10. Regalbutto C, Malandrino P, Tumminia A, Le Moli R, Vigneri R, Pezzino V. A diffuse sclerosing variant of papillary thyroid carcinoma: clinical and pathologic features and outcomes of 34 consecutive cases. *Thyroid*. 2011;21(4):383-389.
11. Rivera M, Tuttle RM, Patel S, Shaha A, Shah JP, Ghossein RA. Encapsulated papillary thyroid carcinoma: a clinico-pathologic study of 106 cases with emphasis on its morphologic subtypes (histologic growth pattern). *Thyroid*. 2009;19(2):119-127.
12. Liu J, Singh B, Tallini G, et al. Follicular variant of papillary thyroid carcinoma: a clinicopathologic study of a problematic entity. *Cancer*. 2006;107(6):1255-1264.
13. Komorowski RA, Hanson GA. Occult thyroid pathology in the young adult: an autopsy study of 138 patients without clinical thyroid disease. *Hum Pathol*. 1988;19(6):689-696.
14. Fink A, Tomlinson G, Freeman JL, Rosen IB, Asa SL. Occult micropapillary carcinoma associated with benign follicular thyroid disease and unrelated thyroid neoplasms. *Mod Pathol*. 1996;9(8):816-820.
15. Niemeier LA, Kuffner Akatsu H, et al. A combined molecular-pathologic score improves risk stratification of thyroid papillary microcarcinoma. *Cancer*. 2012;118(8):2069-2077.

16. Nikiforov YE, Ohori NP. Follicular carcinoma. In: Nikiforov YE, Biddinger PW, Thompson LDR, eds. *Diagnostic Pathology and Molecular Genetics of the Thyroid*. 2nd ed. Philadelphia, PA: Lippincott Williams and Wilkins; 2012:152-182.
17. van Heerden JA, Hay ID, Goellner JR, et al. Follicular thyroid carcinoma with capsular invasion alone: a nonthreatening malignancy. *Surgery*. 1992;112(6):1130-1136; discussion 1136-1138.
18. Volante M, Collini P, Nikiforov YE, et al. Poorly differentiated thyroid carcinoma: the Turin proposal for the use of uniform diagnostic criteria and an algorithmic diagnostic approach. *Am J Surg Pathol*. 2007;31(8):1256-1264.
19. Dettmer M, Schmitt A, Steinert H, et al. Poorly differentiated thyroid carcinomas: how much poorly differentiated is needed? *Am J Surg Pathol*. 2011;35(12):1866-1872.
20. Hiltzik D, Carlson DL, Tuttle RM, et al. Poorly differentiated thyroid carcinomas defined on the basis of mitosis and necrosis: a clinicopathologic study of 58 patients. *Cancer*. 2006;106(6):1286-1295.
21. Rivera M, Ricarte-Filho J, Patel S, et al. Encapsulated thyroid tumors of follicular cell origin with high grade features (high mitotic rate/tumor necrosis): a clinicopathologic and molecular study. *Hum Pathol*. 2010;41(2):172-180.
22. Nikiforov YE, Seethala RR. Anaplastic (undifferentiated) carcinoma. In: Nikiforov YE, Biddinger PW, Thompson LDR, eds. *Diagnostic Pathology and Molecular Genetics of the Thyroid*. 2nd ed. Philadelphia, PA: Lippincott Williams and Wilkins; 2012: 263-284.
23. Sugitani I, Kasai N, Fujimoto Y, Yanagisawa A. Prognostic factors and therapeutic strategy for anaplastic carcinoma of the thyroid. *World J Surg*. 2001;25(5):617-622.
24. Aldinger KA, Samaan NA, Ibanez M, Hill CS, Jr. Anaplastic carcinoma of the thyroid: a review of 84 cases of spindle and giant cell carcinoma of the thyroid. *Cancer*. 1978;41(6):2267-2275.
25. Rosai J, Carcangiu ML, DeLellis RA. *Atlas of Tumor Pathology. Tumors of the Thyroid Gland*. Fascicle 5. 3rd ed. Washington DC: Armed Forces Institute of Pathology; 1992.
26. Mete O, Asa SL. Pathological definition and clinical significance of vascular invasion in thyroid carcinomas of follicular epithelial derivation. *Mod Pathol*. 2011;24(12):1545-1552.
27. Erovcic BM, Kim D, Cassol C, et al. Prognostic and predictive markers in medullary thyroid carcinoma. *Endocr Pathol*. 2012;23(4):232-242.
28. Thompson LD, Wieneke JA, Paal E, Frommelt RA, Adair CF, Heffess CS. A clinicopathologic study of minimally invasive follicular carcinoma of the thyroid gland with a review of the English literature. *Cancer*. 2001;91(3):505-524.
29. Collini P, Sampietro G, Pilotti S. Extensive vascular invasion is a marker of risk of relapse in encapsulated non-Hurthle cell follicular carcinoma of the thyroid gland: a clinicopathological study of 18 consecutive cases from a single institution with a 11-year median follow-up. *Histopathology*. 2004;44(1):35-39.
30. Ghossein RA, Hiltzik DH, Carlson DL, et al. Prognostic factors of recurrence in encapsulated Hurthle cell carcinoma of the thyroid gland: a clinicopathologic study of 50 cases. *Cancer*. 2006;106(8):1669-1676.
31. Stojadinovic A, Ghossein RA, Hoos A, et al. Hurthle cell carcinoma: a critical histopathologic appraisal. *J Clin Oncol*. 2001;19(10):2616-2625.
32. Mete O, Rotstein L, Asa SL. Controversies in thyroid pathology: thyroid capsule invasion and extrathyroidal extension. *Ann Surg Oncol*. 2010;17(2):386-391.
33. Standring S. Thyroid gland. In: Standring S, ed. *Gray's Anatomy. The Anatomical Basis of Clinical Practice*. Edinburgh: Elsevier Churchill Livingstone; 2005:560-564.
34. Gnepp DR, Ogorzalek JM, Heffess CS. Fat-containing lesions of the thyroid gland. *Am J Surg Pathol*. 1989;13(7):605-612.
35. Carty SE, Doherty GM, Inabnet WB 3rd, et al; American Thyroid Association statement on the essential elements of interdisciplinary communication of perioperative information for patients undergoing thyroid cancer surgery. *Thyroid*. 2012;22(4):395-399.
36. Robbins KT, Medina JE, Wolfe GT, Levine PA, Sessions RB, Pruet CW. Standardizing neck dissection terminology: Official report of the Academy's Committee for Head and Neck Surgery and Oncology. *Arch Otolaryngol Head Neck Surg*. 1991;117(6):601-605.
37. Robbins KT, Shaha AR, Medina JE, et al. Consensus statement on the classification and terminology of neck dissection. *Arch Otolaryngol Head Neck Surg*. 2008;134(5):536-538.
38. Cranshaw IM, Carnaille B. Micrometastases in thyroid cancer: an important finding? *Surg Oncol*. 2008;17(3):253-258.

39. Urken ML, Mechanick JI, Sarlin J, Scherl S, Wenig BM. Pathologic reporting of lymph node metastases in differentiated thyroid cancer: a call to action for the College of American Pathologists. *Endocr Pathol*. 2013.
40. Randolph GW, Duh QY, Heller KS, et al. The prognostic significance of nodal metastases from papillary thyroid carcinoma can be stratified based on the size and number of metastatic lymph nodes, as well as the presence of extranodal extension. *Thyroid*. 2012;22(11):1144-1152.
41. Carty SE, Cooper DS, Doherty GM, et al. Consensus statement on the terminology and classification of central neck dissection for thyroid cancer. *Thyroid*. 2009;19(11):1153-1158.
42. Yamashita H, Noguchi S, Murakami N, et al. Extracapsular invasion of lymph node metastasis: a good indicator of disease recurrence and poor prognosis in patients with thyroid microcarcinoma. *Cancer*. 1999;86(5):842-849.
43. Lango M, Flieder D, Arrangoiz R, et al. Extranodal extension of metastatic papillary thyroid carcinoma: correlation with biochemical endpoints, nodal persistence, and systemic disease progression. *Thyroid*. 2013;23(9):1099-1105.
44. Robbins KT, Samant S, Ronen O. Neck dissection. In: Edited by Flint PW, Haughey BH, Lund VJ, et al, eds. *Cummings Otolaryngology. Head and Neck Surgery*. 5th ed. Philadelphia. PA: Saunders; 2005:1702-1725.