

VM111 Bone Marrow Lymphoid Disorders

Kaaren K. Reichard, MD, FCAP

October 1, 2007 4:00 – 5:30 PM

Case 1: Objective: Approach to Interstitial Lymphoid Aggregates in BM

Two exemplary cases: 1) *Benign lymphoid aggregates*
2) *CLL/SLL*

Patient #1: 83-year-old male with mild anemia; history of diabetes on multiple meds

CBC	WBC 3.2, RBC 3.0, Hgb 9.5, MCV 85, Hct 31%, Plt 166K
Blood	Mild normochromic, normocytic anemia
BM	<u>Aspirate</u> : spicular and cellular with trilineage hematopoiesis. <u>Core bx</u> : variably cellular marrow with multiple, small, interstitial, well-circumscribed lymphoid aggregates. Background intact trilineage hematopoiesis and architecture.
IHC	CD20 and CD3 demonstrate an admixture of B- and T-cells respectively with a predominance of T-cells.

Patient #2: 49-year-old female with incidental finding of mild absolute lymphocytosis and mild anemia

CBC	WBC 12.1, RBC 4.5, Hgb 13.8, Hct 40%, Plt 108K
Blood	Mild absolute lymphocytosis, monotonous small lymphoid population with round nuclei, clumped chromatin, inconspicuous nucleoli and scant cytoplasm. Scattered smudge cells in background. Mild thrombocytopenia
BM	<u>Aspirate</u> : Spicular and cellular with trilineage hematopoiesis. ~10% of cells are small, mature lymphocytes. <u>Core bx</u> : Hypercellular with intact architecture and multiple small lymphoid aggregates
Flow Cytometry	Flow demonstrates a ~10% population of monoclonal CD19+ B-cells expressing CD20 (weak), CD5, CD23 and surface kappa (weak) and lacking FMC-7 and CD38 (better prognosis).

Key tips:

- Benign lymphoid aggregates: more frequent in older individuals, generally small, may be multiple, interstitial location, no infiltrative margins, admixture of B- and T-cells, may be seen in patients with connective tissue disease, other autoimmune disorders
- Flow cytometry is very helpful when an adequate aspirate is available
- For discussion: monoclonal B-lymphocytosis of uncertain significance, LGL

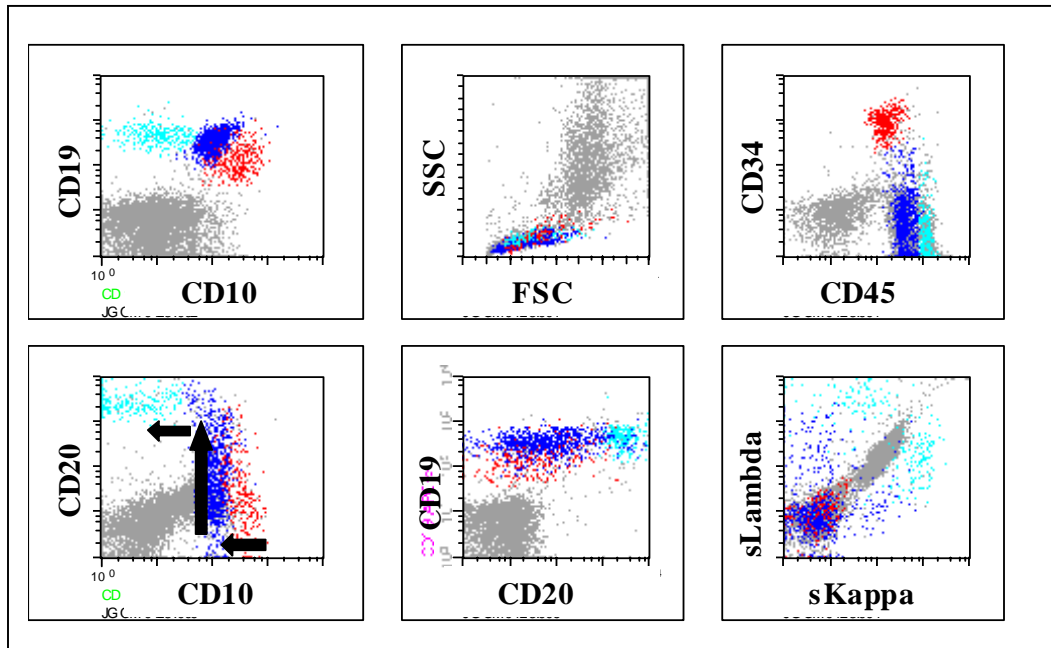
Case 2: Objective: Recognize Morphologic and Immunophenotypic Features of Hematogones, Benign Precursor B-cells in Bone Marrow

Two exemplary cases: 1) Hematogone hyperplasia
 2) B-ALL

Patient #1: 3-year-old male on therapy for precursor B-cell acute lymphoblastic leukemia

CBC	WBC 12.1, RBC 5.5, Hgb 14.7, Hct 42%, MCV 75, Plt 357K
Blood	Unremarkable. No circulating blasts
BM	Aspirate: spicular and cellular with trilineage hematopoiesis. Conspicuous population of lymphoid cells, many slightly larger in size with condensed, homogeneous, smooth chromatin and scant cytoplasm. Core bx: Normocellular marrow with trilineage hematopoiesis and intact architecture. Lymphoid cells are morphologically inconspicuous.

Flow cytometry on bone marrow aspirate demonstrate hematogones



VM111 Bone Marrow Lymphoid Disorders

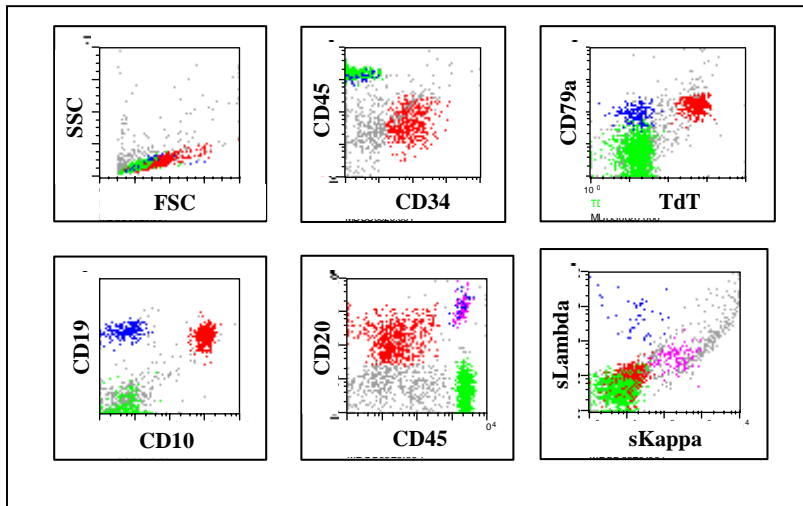
Kaaren K. Reichard, MD, FCAP

Case 2 (cont'd)

Patient #2: 17-month-old female with profound anemia

CBC	WBC 15.2, RBC 1.3, Hgb 3.8, MCV 84, Hct 11%, Plt 222K
Blood	Profound isolated anemia, but normochromic/normocytic with no evidence of hemolysis. Intact neutrophils and platelets. Circulating blasts.
BM	Not performed.

Flow cytometry on peripheral blood demonstrates B- lymphoblasts



Key tips for discriminating hematogones:

- Morphologic clues: Variably-sized lymphoid cells with condensed, “smudgy”, homogeneous chromatin and generally lacking nucleoli. Nuclear contours may occasionally be slightly irregular and the cytoplasm is scant providing a diagnostic dilemma with true lymphoblasts. The presence of vacuoles or small granules in the cytoplasm should prompt consideration of lymphoblasts.
- Immunophenotypic clues: Hematogones demonstrate a spectrum of maturation by both flow cytometry (FC) and immunohistochemistry (IHC). By IHC, TdT positive cells are much less numerous than CD79a and CD20 positive cells, and the TdT positive cells do not exhibit clusters of greater than 5-6 cells. By FC, the pattern of maturation from most immature (e.g. hematogone) to the most mature B-cell is readily identified. The most immature are CD10 bright positive, CD34 and TdT positive, weak CD19+, weak CD45+ and lack CD20. As hematogones mature, CD19 and CD45 increase in intensity, CD10 is lost and CD20 and surface immunoglobulin are acquired.

Case 3: Objective: Value of Patterns of Bone Marrow Infiltration in Lymphoma

Two exemplary cases of splenic marginal zone lymphoma (SMZL) with BM infiltration

Patient #1: 54-year-old male with chronic lymphocytosis and splenomegaly

CBC	WBC 13.4, RBC 4.0, Hgb 12.3, Hct 37%, Plt 249K
Blood	Absolute lymphocytosis, spectrum of lymphocyte morphology, some with shaggy contours; rouleaux; <u>normal</u> numbers of neutrophils and monocytes
BM	Dry tap; large <u>discrete</u> lymphoid nodules on core biopsy; distinct zoning of lymphoid nodules, rare germinal center. Marked predominance of B lymphocytes with focal non-paratrabeular and <u>sinusoidal</u> infiltrates

Patient #2: 61-year-old female with chronic lymphocytosis and splenomegaly

CBC	WBC 3.9, RBC 4.1, Hgb 9.9, Hct 31%, Plt 180K
Blood	Atypical lymphocytosis (abundant cytoplasm, shaggy contours); <u>normal</u> neutrophil and monocyte counts
BM	Hypercellular with intact architecture; <u>no</u> evidence of abnormal infiltrate on H&E (<u>very inconspicuous</u>); CD20 highlights unique <u>purely</u> sinusoidal infiltrate of B cells

Additional tests:

Patient 1	Flow cytometry	Monoclonal B cell, CD10- , CD5- , <u>weak CD11c</u> , <u>CD25-</u> , <u>CD103-</u>
Patient 2	Flow cytometry	Monoclonal B cell, <u>bright CD11c</u> , <u>weak CD22</u> , <u>CD25-</u> , <u>CD103-</u>
	Cytogenetics	Inv(7) <i>Note: Abnormalities of chromosome 7 involving 7q32 described in SMZL</i>

Key Tips:

- Differential diagnosis of SMZL versus HCL and atypical CLL is challenging. For purposes of treatment and prognosis it is very important to make the distinction.
- **HCL:**
 - Cytopenias including leukopenia, neutropenia, and monocytopenia
 - Rare hairy cells in blood
 - Subtle diffuse interstitial infiltrates highlighted by CD20 (BM biopsy)
 - IP: Strong CD22/CD11c coexpression, CD103+, CD25 usually +
- **Atypical lymphocytosis with shaggy contours:**
 - Assess for splenomegaly
 - Assess blood for monocytes
 - BM core biopsy- discrete lesions very unusual in HCL, characteristic of SMZL; sinusoid component very characteristic of SMZL but also seen in HCL

Case 4: Objective: Approach to Cases with Marked Lymphocytosis

Patient: 49-year-old male with hepatosplenomegaly and striking leukocytosis

CBC	WBC 200K, RBC 3.0, Hgb 11, Hct 37%, Plt 47K
Blood	Striking <u>mature</u> lymphocytosis with round to slightly irregular nuclear contours and variably prominent nucleoli (generally <u>inconspicuous</u>)
BM	Not available; presumed diffuse effacement

Additional studies:

Flow cytometry Mature T-cell population with coexpression of CD4 and CD8, CD2+ , CD3+ , CD5+ , CD7+ , bright CD45+ ; TdT-

Cytogenetics 42-44,XY,inv(14)(q11q32) plus numerous other abnormalities

Key Tips:

- Differential diagnosis of extreme lymphocytosis includes B-PLL, T-PLL, ALL, and (less likely) CLL, ATLL, others
- Flow cytometry critical: T vs. B, mature vs. immature
- T-PLL more common than B-PLL (both associated with hepatosplenomegaly; effusions and skin lesions more common in T-PLL)
- One quarter of T-PLL cases exhibit CD4, CD8 coexpression
- Cytogenetics valuable: inv(14)(q11q32) characteristic of T-PLL
- **Therapy:** Campath-1-H: humanized monoclonal antibody to CD52 recently shown to be effective in T-PLL
- For discussion: comparison with case of B-PLL and infant B-ALL

Case 5: Objective: Approach to Cases with Plasmacytic/Plasmablastic Differentiation

Two exemplary cases: 1) *Plasma Cell Myeloma*
 2) *Lymphoplasmacytic Lymphoma*

Patient #1: 42-year-old female presents with mediastinal mass and bilateral supraclavicular lymphadenopathy. Later studies reveal IgA M-protein and lytic lesions.

CBC	WBC 3.2, RBC 2.3, Hgb 8.3, Hct 24%, Plt 27K
Blood	Anemia with prominent rouleaux formation. Circulating, markedly atypical plasma cells. Thrombocytopenia.
BM	<u>Aspirate:</u> Aspicular and hemodilute. Touch prep shows numerous malignant plasma cells, many with plasmablastic features (large cells with dispersed chromatin, prominent large nucleolus). <u>Core bx:</u> Hypercellular marrow with neoplastic plasma cells, comprising ~50% of nucleated cells, in an interstitial and diffuse pattern. <u>IHC on core bx:</u> Neoplastic cells are CD79a, ALK, HHV-8 and EBER (-)
Flow Cytometry	50% monoclonal population with a plasma cell immunophenotype: CD38 and CD138 bright+, cytoplasmic kappa+, and negative for CD19, CD20, CD45 and CD56.
Cytogenetics	50,XX,add(1)(p13),+7,-8,t(8;14)(q24.1;q32),+9,+11, der(14)t(8;14)(q24.1;q32), +18, +mar[2]/45-50,X,-X,add(1)(p13),del(3)(q21),+del(3)(q21),+7,-8,t(8;14)(q24.1;q32),+11,der(14)t(8;14)(q24.1;q32),+18,+21,+22,+mar[cp16]/46,XX[2]

Patient #2: 54-year-old male with IgM kappa M-protein (4.4.g/dl) and hypogammaglobulinemia.

CBC	WBC 7.1, RBC 3.6, Hgb 11.9, Hct 34%, Plt 389K
Blood	Mild anemia with rouleaux formation. Rare atypical lymphoplasmacytic cells
BM	<u>Aspirate:</u> increase mature-appearing plasma cells and a spectrum of lymphocyte morphology from mature lymphoid to lymphoplasmacytic. Occasional Dutcher bodies and increased mast cells. <u>Core bx:</u> extensive lymphoplasmacytic infiltrate in an interstitial and diffuse pattern
Flow Cytometry	Monoclonal B-cell (CD5- and CD10-) and small monoclonal plasma cell.

Key Tips:

- Distinction from other “plasmablastic” lesions can be challenging. Correlate with HIV status, EBV in situ, SPEP/UPEP and radiologic studies.
- Other low grade B-cell LPDO’s may have an associated M-protein/plasmacytosis. Definitive distinction from SMZL is critical for prognosis and treatment.

Case 6: Objective: Approach to Large Cell Lesions in Bone Marrow

Two exemplary cases: 1) *Large B-cell lymphoma*
 2) *Classical Hodgkin Lymphoma*

Patient #1: 86-year-old female with intact peripheral counts until the recent past

CBC	WBC 13.5, RBC 2.2, Hgb 6.5, Hct 20%, MCV 88, Plt 10K
Blood	Marked anemia with circulating nRBC's, left shift and thrombocytopenia
BM	<u>Aspirate:</u> Dry tap. <u>Core bx:</u> Hypercellular marrow with interstitial and focally diffuse involvement by a large neoplastic cell infiltrate. The cells have blastoid chromatin and have nuclear contour irregularities and lobations. Background hematopoiesis is seen.

Patient #2: 54-year-old male with recently diagnosed classical Hodgkin lymphoma in LN

CBC	WBC 5.8, RBC 4.9, Hgb 12.4, Hct 37%, MCV 80, Plt 150K
Blood	Mild normochromic, normocytic anemia; otherwise unremarkable
BM	<u>Aspirate:</u> Hypercellular with atypical clusters of large neoplastic cells surrounded by eosinophils, plasma cells and small lymphoid cells. Background hematopoiesis is seen. <u>Core bx:</u> Hypercellular marrow infiltrated by large neoplastic cells with morphologic features consistent with R-S cells and Hodgkin variants. These cells are accompanied by plasma cells, eosinophils and lymphocytes. Background trilineage hematopoiesis is also seen.

Key Tips:

- Large cell lesions can be very difficult to classify in bone marrow.
- IHC may be technically suboptimal due to decalcification; flow often inadequate (insufficient material, insufficient neoplastic cells, etc.)
- Hodgkin lymphoma and non-Hodgkin lymphoma may be morphologically similar including a fibrotic and surrounding mixed inflammatory milieu.
- For discussion, TCRLBCL post chemo and Rituxan→mimics cHL!