

Protocol for the Examination of Specimens from Patients with Carcinoma of the Ampulla of Vater

Protocol applies to all intra-ampullary, peri-ampullary, and mixed intra- and peri-ampullary carcinomas. Well-differentiated neuroendocrine neoplasms (carcinoid tumors) are not included.

Based on AJCC/UICC TNM, 7th edition

Protocol web posting date: October 2009

Procedures

- Ampullectomy
- Pancreaticoduodenectomy (Whipple Resection)

Authors

Kay Washington, MD, PhD, FCAP*

Department of Pathology, Vanderbilt University Medical Center, Nashville, TN
Jordan Berlin, MD

Department of Medicine, Vanderbilt University Medical Center, Nashville, TN

Philip Branton, MD, FCAP

Department of Pathology, Inova Fairfax Hospital, Falls Church, VA

Lawrence J. Burgart, MD, FCAP

Allina Laboratories, Abbott Northwestern Hospital, Minneapolis, MN

David K. Carter, MD, FCAP

Department of Pathology, St. Mary's/Duluth Clinic Health System, Duluth, MN

Carolyn C. Compton, MD, PhD, FCAP

Office of Biorepositories and Biospecimen Research, National Cancer Institute, Bethesda, MD

Patrick Fitzgibbons, MD, FCAP

Department of Pathology, St. Jude Medical Center, Fullerton, CA

Wendy L. Frankel, MD, FCAP

Department of Pathology, Ohio State University Medical Center, Columbus, OH

John Jessup, MD

Division of Cancer Treatment and Diagnosis, National Cancer Institute, Bethesda, MD

Sanjay Kakar, MD, FCAP

Department of Pathology, University of California San Francisco and the Veterans Affairs Medical Center, San Francisco, CA

Bruce Minsky, MD

Department of Radiation Oncology, University of Chicago, Chicago, IL

Raouf Nakhleh, MD, FCAP

Department of Pathology, Mayo Clinic, Jacksonville, FL

Jean-Nicolas Vauthey, MD

Department of Surgical Oncology, University of Texas MD Anderson Cancer Center, Houston, TX†

For the Members of the Cancer Committee, College of American Pathologists

*denotes primary author. † denotes senior author. All other contributing authors are listed alphabetically.

© 2009 College of American Pathologists (CAP). All rights reserved.

The College does not permit reproduction of any substantial portion of these protocols without its written authorization. The College hereby authorizes use of these protocols by physicians and other health care providers in reporting on surgical specimens, in teaching, and in carrying out medical research for nonprofit purposes. This authorization does not extend to reproduction or other use of any substantial portion of these protocols for commercial purposes without the written consent of the College.

The CAP also authorizes physicians and other health care practitioners to make modified versions of the Protocols solely for their individual use in reporting on surgical specimens for individual patients, teaching, and carrying out medical research for non-profit purposes.

The CAP further authorizes the following uses by physicians and other health care practitioners, in reporting on surgical specimens for individual patients, in teaching, and in carrying out medical research for non-profit purposes: (1) **Dictation** from the original or modified protocols for the purposes of creating a text-based patient record on paper, or in a word processing document; (2) **Copying** from the original or modified protocols into a text-based patient record on paper, or in a word processing document; (3) The use of a **computerized system** for items (1) and (2), provided that the Protocol data is stored intact as a single text-based document, and is not stored as multiple discrete data fields.

Other than uses (1), (2), and (3) above, the CAP does not authorize any use of the Protocols in electronic medical records systems, pathology informatics systems, cancer registry computer systems, computerized databases, mappings between coding works, or any computerized system without a written license from CAP. Applications for such a license should be addressed to the SNOMED Terminology Solutions division of the CAP.

Any public dissemination of the original or modified Protocols is prohibited without a written license from the CAP.

The College of American Pathologists offers these protocols to assist pathologists in providing clinically useful and relevant information when reporting results of surgical specimen examinations of surgical specimens. The College regards the reporting elements in the "Surgical Pathology Cancer Case Summary (Checklist)" portion of the protocols as essential elements of the pathology report. However, the manner in which these elements are reported is at the discretion of each specific pathologist, taking into account clinician preferences, institutional policies, and individual practice.

The College developed these protocols as an educational tool to assist pathologists in the useful reporting of relevant information. It did not issue the protocols for use in litigation, reimbursement, or other contexts. Nevertheless, the College recognizes that the protocols might be used by hospitals, attorneys, payers, and others. Indeed, effective January 1, 2004, the Commission on Cancer of the American College of Surgeons mandated the use of the checklist elements of the protocols as part of its Cancer Program Standards for Approved Cancer Programs. Therefore, it becomes even more important for pathologists to familiarize themselves with these documents. At the same time, the College cautions that use of the protocols other than for their intended educational purpose may involve additional considerations that are beyond the scope of this document.

The inclusion of a product name or service in a CAP publication should not be construed as an endorsement of such product or service, nor is failure to include the name of a product of service to be construed as disapproval.

Surgical Pathology Cancer Case Summary (Checklist)

Protocol web posting date: October 2009

AMPULLA OF VATER: Ampullectomy, Pancreaticoduodenectomy (Whipple Resection)

Select a single response unless otherwise indicated.

Specimen (select all that apply)

Ampulla of Vater

Other organs received:

Stomach

Head of pancreas

Duodenum

Common bile duct

Gallbladder

Other (specify): _____

Not specified

Procedure

Ampullectomy

Pancreaticoduodenectomy (Whipple resection)

Other (specify): _____

Not specified

Tumor Site (Note A)

Intra-ampullary

Peri-ampullary

Papilla of Vater (junction of ampullary and duodenal mucosa)

Other (specify): _____

Cannot be determined

Not specified

Tumor Size (Note B)

Greatest dimension: ____ cm

*Additional dimensions: ____ x ____ cm

Cannot be determined (see Comment)

* Data elements with asterisks are not required. However, these elements may be clinically important but are not yet validated or regularly used in patient management.

Histologic Type (Note C)

- Adenocarcinoma (not otherwise characterized)
 Papillary adenocarcinoma
 Adenocarcinoma, intestinal type
 Mucinous adenocarcinoma
 Clear cell adenocarcinoma
 Signet-ring cell carcinoma
 Adenosquamous carcinoma
 Squamous cell carcinoma
 Small cell carcinoma
 Other (specify): _____
 Carcinoma, not otherwise specified

Histologic Grade (Note D)

- Not applicable (histologic type not usually graded)
 GX: Cannot be assessed
 G1: Well differentiated
 G2: Moderately differentiated
 G3: Poorly differentiated
 G4: Undifferentiated
 Other (specify): _____

Microscopic Tumor Extension (select all that apply)

- Cannot be assessed
 No evidence of primary tumor
 Carcinoma in situ
 Tumor limited to ampulla of Vater or sphincter of Oddi
 Tumor invades duodenal wall
 Tumor invades pancreas
 Tumor invades peripancreatic soft tissues
 Tumor invades extrapancreatic common bile duct
 Tumor invades other adjacent organs or structures other than pancreas
 (specify): _____

Margins (select all that apply) (Note E)Ampullectomy Specimen

- Cannot be assessed
 Margins uninvolved by invasive carcinoma
 Distance of invasive carcinoma from closest margin: ____ mm
 Specify margin (if possible): _____
 Margins involved by invasive carcinoma
 Specify margin(s) (if possible): _____
 Not applicable

* Data elements with asterisks are not required. However, these elements may be clinically important but are not yet validated or regularly used in patient management.

Pancreaticoduodenal Resection Specimen*Proximal Mucosal Margin (Gastric or Duodenal)*

- Cannot be assessed
 Uninvolved by invasive carcinoma
 Involved by invasive carcinoma
 Intramucosal carcinoma /adenoma not identified at proximal margin
 Intramucosal carcinoma/adenoma present at proximal margin

Distal Margin (Distal Duodenal or Jejunal)

- Cannot be assessed
 Uninvolved by invasive carcinoma
 Involved by invasive carcinoma
 Intramucosal carcinoma/adenoma not identified at distal margin
 Intramucosal carcinoma /adenoma present at distal margin

Pancreatic Retroperitoneal (Uncinate) Margin

- Not applicable
 Cannot be assessed
 Uninvolved by invasive carcinoma
 Involved by invasive carcinoma (tumor present 0-1 mm from margin)

Bile Duct Margin

- Not applicable
 Cannot be assessed
 Margin uninvolved by invasive carcinoma
 Margin involved by invasive carcinoma

Distal Pancreatic Resection Margin

- Not applicable
 Cannot be assessed
 Margin uninvolved by invasive carcinoma
 Margin involved by invasive carcinoma

If all margins uninvolved by invasive carcinoma:

Distance of invasive carcinoma from closest margin: ___ mm OR ___ cm

Specify margin: _____

Lymph-Vascular Invasion (Note B)

- Not identified
 Present
 Indeterminate

***Perineural Invasion (Note B)**

- Not identified
 Present
 Indeterminate

* Data elements with asterisks are not required. However, these elements may be clinically important but are not yet validated or regularly used in patient management.

Pathologic Staging (pTNM) (Note F)

TNM Descriptors (required only if applicable) (select all that apply)

- m (multiple primary tumors)
 r (recurrent)
 y (post-treatment)

Primary Tumor (pT)

- pTX: Cannot be assessed
 pT0: No evidence of primary tumor
 pTis: Carcinoma in situ
 pT1: Tumor limited to ampulla of Vater or sphincter of Oddi
 pT2: Tumor invades duodenal wall
 pT3: Tumor invades pancreas
 pT4: Tumor invades peripancreatic soft tissues or other adjacent organs or structures

Regional Lymph Nodes (pN)

- pNX: Cannot be assessed
 pN0: No regional lymph node metastasis
 pN1: Regional lymph node metastasis
Specify: Number examined: ____
Number involved: ____

Distant Metastasis (pM)

- Not applicable
 pM1: Distant metastasis
*Specify site(s), if known: _____

***Additional Pathologic Findings (select all that apply)**

- * None identified
* Dysplasia/adenoma
* Other (specify): _____

***Ancillary Studies**

- *Specify: _____
* Not performed

***Clinical History (select all that apply) (Note G)**

- * Familial adenomatous polyposis coli
* Other (specify): _____
* Not known

***Comment(s)**

* Data elements with asterisks are not required. However, these elements may be clinically important but are not yet validated or regularly used in patient management.

Explanatory Notes

A. Anatomical Considerations

The ampulla of Vater is a complex structure that usually represents the confluence of the distal common bile duct and main pancreatic duct (Figure 1). In some individuals the ampulla includes only the distal common bile duct, with the pancreatic duct entering the duodenum elsewhere. The ampulla traverses the duodenal wall and opens into the duodenal lumen through a small mucosal elevation, the duodenal papilla (Figure 1). The ampulla is lined by pancreatobiliary type ductal epithelium, whereas the duodenal papilla is covered by small intestinal epithelium. The sphincter of Oddi is part of the ampulla and consists of smooth muscle fibers that surround the distal end of the merged ducts.

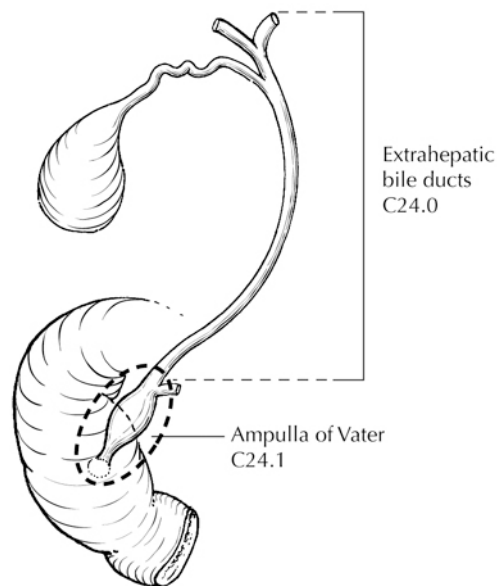


Figure 1. Anatomy of the ampulla of Vater. From Greene et al.¹³ Used with permission of the American Joint Committee on Cancer (AJCC), Chicago, Illinois. The original source for this material is the *AJCC Cancer Staging Atlas* (2006) published by Springer Science and Business Media LLC, www.springerlink.com.

Tumors of the ampulla of Vater may arise in the ampulla (intra-ampullary type) or on the duodenal surface of the papilla (peri-ampullary type),¹ or may involve both the intra-ampullary and peri-ampullary regions (mixed type). Thus, ampullary tumors may show biliary and/or intestinal features. The origin of the tumor may be difficult, and occasionally impossible, to determine; the differential diagnosis includes carcinoma of the distal common bile duct, main pancreatic duct, and duodenum. Tumors may be exophytic or ulcerated.

B. Non-TNM Prognostic Factors

Although not included in the TNM staging system for tumors of the ampulla of Vater, tumor size has been shown to have independent prognostic significance for local recurrence.² In some series, pancreatic invasion, not tumor size, appears to be the more important prognostic factor.³

Lymph and small blood vessel invasion⁴ and perineural invasion⁵ have also been shown to be adverse prognostic factors.

C. Histologic Type

This protocol uses the following histologic classification but does not preclude the use of other histologic types or systems of classification. A modified classification of carcinomas of the gallbladder and extrahepatic bile ducts published by the World Health Organization (WHO) that is applicable to the ampulla of Vater is as follows:⁶

WHO Classification of Ampullary Carcinoma

Adenocarcinoma
 Papillary adenocarcinoma[#]
 Adenocarcinoma, intestinal type
 Mucinous adenocarcinoma
 Clear cell adenocarcinoma
 Signet-ring cell carcinoma^{##}
 Adenosquamous carcinoma
 Squamous cell carcinoma
 Small cell carcinoma^{###}
 Large cell neuroendocrine carcinoma
 Undifferentiated carcinoma^{###}

The term “carcinoma, NOS (not otherwise specified)” is not part of the WHO classification.

[#] Ampullary tumors of the papillary histologic type have been shown to have a favorable prognosis as compared with tumors of nonpapillary histologic types. Many of these tumors have a noninvasive exophytic growth pattern and hence a favorable prognosis. These tumors are more common in the gallbladder than in the ampullary region.¹

^{##} Signet-ring cell carcinomas are, by convention, classified as poorly differentiated (grade 3) adenocarcinomas.

^{###} Small cell carcinomas and undifferentiated (histologic type) carcinomas are assigned grade 4 (see below).

D. Histologic Grade

For nonpapillary adenocarcinomas, the following grading system is suggested:

GX Grade cannot be assessed
 G1 Well differentiated (greater than 95% of tumor composed of glands)
 G2 Moderately differentiated (50% to 95% of tumor composed of glands)
 G3 Poorly differentiated[#] (49% or less of tumor composed of glands)

[#] Poor differentiation has been shown to be an adverse prognostic factor on univariate analysis in some, but not all, series.^{2,7}

Grade 4 carcinomas include both undifferentiated carcinomas (histologic type) and small cell carcinoma (high-grade neuroendocrine carcinomas) in the WHO classification (see above). Undifferentiated carcinomas should show less than 5% glandular structures.

E. Margins

Local recurrence from invasive carcinoma in the region of the pancreatic head, including ampullary cancers invading the pancreas, most often occurs at the uncinata margin of the pancreatic head (retroperitoneal margin). Because this is a critical margin, inking the retroperitoneal surface of the pancreas and submitting sections through the tumor at its closest approach to this margin is recommended. Complete en face sections through the distal pancreatic resection margin (representing the distal margin of the main pancreatic duct) and the resection margin of the common bile duct should also be taken. Microscopically positive margins of resection (R1) have been shown to have an adverse impact on prognosis in ampullary carcinoma.⁸

F. TNM and Anatomic Stage/Prognostic Groupings

The TNM staging system for tumors of the ampulla of Vater of the American Joint Committee on Cancer (AJCC) and the International Union Against Cancer (UICC) is recommended and shown below.⁹ The post-resection prognosis of a patient with ampullary carcinoma is primarily determined by the anatomic extent of disease as defined by the TNM classification and stage groupings.^{2,7,8}

By AJCC/UICC convention, the designation “T” refers to a primary tumor that has not been previously treated. The symbol “p” refers to the pathologic classification of the TNM, as opposed to the clinical classification, and is based on gross and microscopic examination. pT entails a resection of the primary tumor or biopsy adequate to evaluate the highest pT category, pN entails removal of nodes adequate to validate lymph node metastasis, and pM implies microscopic examination of distant lesions. Clinical classification (cTNM) is usually carried out by the referring physician before treatment during initial evaluation of the patient or when pathologic classification is not possible.

Pathologic staging is usually performed after surgical resection of the primary tumor. Pathologic staging depends on pathologic documentation of the anatomic extent of disease, whether or not the primary tumor has been completely removed. If a biopsied tumor is not resected for any reason (eg, when technically infeasible) and if the highest T and N categories or the M1 category of the tumor can be confirmed microscopically, the criteria for pathologic classification and staging have been satisfied without total removal of the primary cancer.

TNM Descriptors

For identification of special cases of TNM or pTNM classifications, the “m” suffix and “y” and “r” prefixes are used. Although they do not affect the stage grouping, they indicate cases needing separate analysis.

The “m” suffix indicates the presence of multiple primary tumors in a single site and is recorded in parentheses: pT(m)NM.

The “y” prefix indicates those cases in which classification is performed during or after initial multimodality therapy (ie, neoadjuvant chemotherapy, radiation therapy, or both chemotherapy and radiation therapy). The cTNM or pTNM category is identified by a “y” prefix. The ycTNM or ypTNM categorizes the extent of tumor actually present at the time of that examination. The “y” categorization is not an estimate of tumor before multimodality therapy (ie, before initiation of neoadjuvant therapy).

The “r” prefix indicates a recurrent tumor when staged after a documented disease-free interval and is identified by the “r” prefix: rTNM.

T Category Considerations

pTis. For ampullary carcinomas, "carcinoma in situ" (pTis) as a staging term includes cancer cells confined within the glandular basement membrane (high-grade dysplasia). The term “carcinoma in situ” is not widely applied to glandular neoplastic lesions in the gastrointestinal tract but is retained for tumor registry reporting purposes as specified by law in many states. Noninvasive ampullary carcinomas with a papillary growth pattern are classified as pTis.

N Category Considerations

Regional lymph node metastases have been shown to have independent significance as an adverse prognostic factor in multiple series.^{2,10,11} Although a minimum number of lymph nodes has not been determined for optimal staging, retrieval and examination of at least 10 lymph nodes is recommended for pancreaticoduodenectomy.

The regional nodes (Figure 2) may be subdivided as follows:

- Superior: Lymph nodes superior to head and body of pancreas
- Inferior: Lymph nodes inferior to head and body of pancreas
- Anterior: Anterior pancreaticoduodenal, pyloric, and proximal mesenteric lymph nodes
- Posterior: Posterior pancreaticoduodenal, common bile duct or pericholedochal, and proximal mesenteric nodes

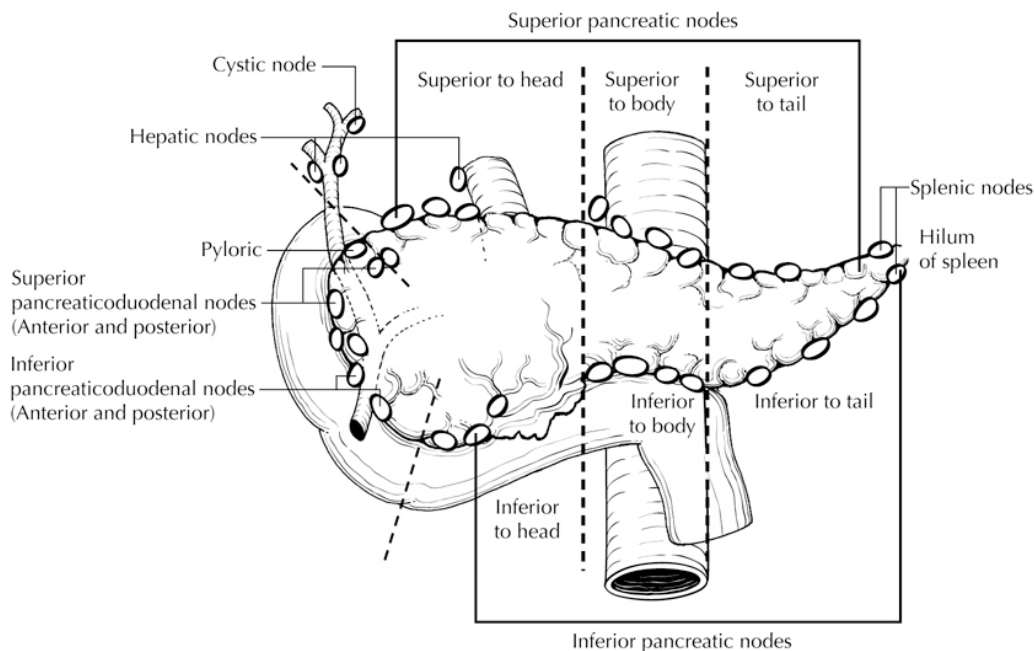


Figure 2. Regional lymph nodes of the ampulla of Vater. From Greene et al.¹³ Used with permission of the American Joint Committee on Cancer (AJCC), Chicago, Illinois. The original source for this material is the *AJCC Cancer Staging Atlas* (2006) published by Springer Science and Business Media LLC, www.springerlink.com.

The following lymph nodes are also considered regional: hepatic artery nodes, infrapyloric nodes, subpyloric nodes, celiac nodes, superior mesenteric nodes, retroperitoneal nodes, and lateral aortic nodes. Tumor involvement of other nodal groups is considered distant metastasis. Anatomic division of regional lymph nodes is not necessary, but separately submitted lymph nodes should be reported as submitted.¹

Routine assessment of regional lymph nodes is limited to conventional pathologic techniques (gross assessment and histologic examination), and data are currently insufficient to recommend special measures to detect micrometastasis or isolated tumor cells. Thus, neither multiple levels of paraffin blocks nor the use of special/ancillary techniques such as immunohistochemistry are recommended for routine examination of regional lymph nodes.

Primary Tumor (T) (Figures 3-6)

TX	Cannot be assessed
T0	No evidence of primary tumor
Tis	Carcinoma in situ
T1	Tumor limited to ampulla of Vater or sphincter of Oddi
T2	Tumor invades duodenal wall
T3	Tumor invades pancreas
T4	Tumor invades peripancreatic soft tissues or other adjacent organs or structures other than pancreas

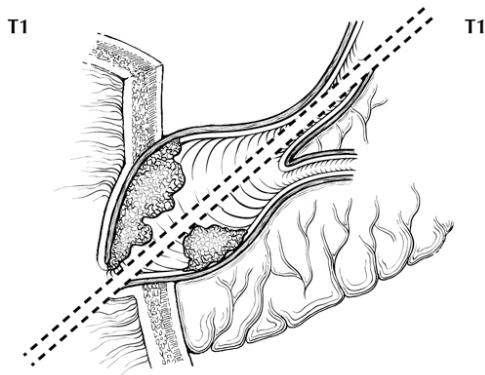


Figure 3. T1 tumors are limited to the ampulla of Vater (below the dotted line) or sphincter of Oddi (above the dotted line). From Greene et al.¹³ Used with permission of the American Joint Committee on Cancer (AJCC), Chicago, Illinois. The original source for this material is the *AJCC Cancer Staging Atlas* (2006) published by Springer Science and Business Media LLC, www.springerlink.com.

T2

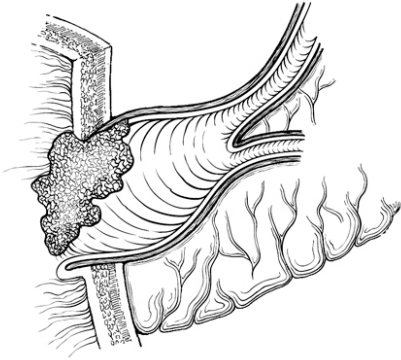


Figure 4. T2 tumors invade the duodenal wall. From Greene et al.¹³ Used with permission of the American Joint Committee on Cancer (AJCC), Chicago, Illinois. The original source for this material is the *AJCC Cancer Staging Atlas* (2006) published by Springer Science and Business Media LLC, www.springerlink.com.

T3

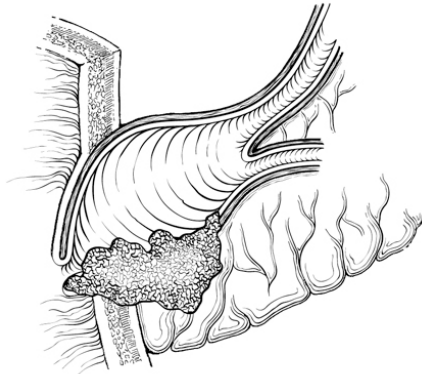


Figure 5. T3 tumors invade pancreas. From Greene et al.¹³ Used with permission of the American Joint Committee on Cancer (AJCC), Chicago, Illinois. The original source for this material is the *AJCC Cancer Staging Atlas* (2006) published by Springer Science and Business Media LLC, www.springerlink.com.

T4

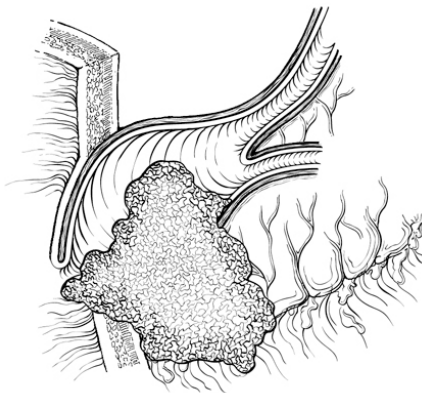


Figure 6. T4 tumors invade peripancreatic soft tissues or other adjacent organs or structures. From Greene et al.¹³ Used with permission of the American Joint Committee on Cancer (AJCC), Chicago, Illinois. The original source for this material is the *AJCC Cancer Staging Atlas* (2006) published by Springer Science and Business Media LLC, www.springerlink.com.

Regional Lymph Nodes (N)

NX	Cannot be assessed
N0	No regional lymph node metastasis
N1	Regional lymph node metastasis

Distant Metastasis (M)

M0	No distant metastasis
M1	Distant metastasis

Stage Groupings

Stage 0	Tis	N0	M0
Stage IA	T1	N0	M0
Stage IB	T2	N0	M0
Stage IIA	T3	N0	M0
Stage IIB	T1	N1	M0
	T2	N1	M0
	T3	N1	M0
Stage III	T4	Any N	M0
Stage IV	Any T	Any N	M1

Vessel Invasion

By AJCC/UICC convention, vessel invasion (lymphatic or venous) does not affect the T category indicating local extent of tumor unless specifically included in the definition of a T category.

G. Relevant Clinical History

Ampullary adenomas are common in patients with familial adenomatous polyposis coli, and such patients are at increased risk for ampullary adenocarcinomas. Estimated lifetime incidence is roughly 12% for ampullary carcinoma in this population.¹²

References

1. Albores-Saavedra J, Henson DE, Klimstra DS. *Tumors of the Gallbladder, Extrahepatic Bile Ducts, and Ampulla of Vater*. Vol 27. Third Series ed. Washington, DC: Armed Forces Institute of Pathology; 1998.
2. Hsu HP, Yang TM, Hsieh YH, Shan YS, Lin PW. Predictors for patterns of failure after pancreaticoduodenectomy in ampullary cancer. *Ann Surg Oncol*. 2007;14(1):50-60.
3. Beger HG, Treitschke F, Gansauge F, Harada N, Hiki N, Matfeldt T. Tumor of the ampulla of Vater: experience with local or radical resection in 171 consecutively treated patients. *Arch Surg*. 1999;134:526-532.
4. Bouvet M, Gamagami RA, Gilpin EA, et al. Factors influencing survival after resection for periampullary neoplasms. *Am J Surg*. 2000;180(1):13-17.
5. Bettschart V, Rahman MQ, Engelken FJ, Madhavan KK, Parks RW, Garden OJ. Presentation, treatment and outcome in patients with ampullary tumours. *Br J Surg*. Dec 2004;91(12):1600-1607.
6. Albores-Saavedra J, Scoazec JC, Wittekind C, et al. Carcinoma of the gallbladder and extrahepatic bile ducts. In: Hamilton SR, Aaltonen LA, eds. *World Health Organization Classification of Tumours: Pathology and Genetics of Tumours of the Digestive System*. Lyon, France: IARC Press; 2000:203-214.

7. Kim RD, Kundhal PS, McGilvray ID, et al. Predictors of failure after pancreaticoduodenectomy for ampullary carcinoma. *J Am Coll Surg*. Jan 2006;202(1):112-119.
8. Todoroki T, Koike N, Morishita Y, et al. Patterns and predictors of failure after curative resections of carcinoma of the ampulla of Vater. *Ann Surg Oncol*. Dec 2003;10(10):1176-1183.
9. Edge SB, Byrd DR, Carducci MA, Compton CC, eds. *AJCC Cancer Staging Manual*. 7th ed. New York, NY: Springer; 2009.
10. Riall TS, Cameron JL, Lillemoe KD, et al. Resected periampullary adenocarcinoma: 5-year survivors and their 6- to 10-year follow-up. *Surgery*. 2006;140(5):764-772.
11. Sakata J, Shirai Y, Wakai T, et al. Number of positive lymph nodes independently affects long-term survival after resection in patients with ampullary carcinoma. *Eur J Surg Oncol*. Apr 2007;33(3):346-351.
12. Alexander JR, Andrews JM, Buchi KN, Lee RG, Becker JM, Burt RW. High prevalence of adenomatous polyps of the duodenal papilla in familial adenomatous polyposis. *Dig Dis Sci*. 1989;34:167-170.
13. Greene FL, Compton, CC, Fritz AG, et al, eds. *AJCC Cancer Staging Atlas*. New York, NY: Springer; 2006.