

# Protocol for the Examination of Specimens From Patients With Carcinoma of the Esophagus

**Protocol applies to all carcinomas of the esophagus, including esophagogastric junction carcinomas. Well-differentiated neuroendocrine tumors (carcinoid tumors) are not included.**

---

**Based on AJCC/UICC TNM, 7th edition**

Protocol web posting date: October 2009

## Procedures

- Endoscopic Resection
- Esophagectomy
- Esophagogastrectomy

## Authors

Kay Washington, MD, PhD, FCAP\*

Department of Pathology, Vanderbilt University Medical Center, Nashville, TN  
Jordan Berlin, MD

Department of Medicine, Vanderbilt University Medical Center, Nashville, TN  
Philip Branton, MD, FCAP

Department of Pathology, Inova Fairfax Hospital, Falls Church, VA  
Lawrence J. Burgart, MD, FCAP

Allina Laboratories, Abbott Northwestern Hospital, Minneapolis, MN  
David K. Carter, MD, FCAP

Department of Pathology, St. Mary's/Duluth Clinic Health System, Duluth, MN  
Patrick Fitzgibbons, MD, FCAP

Department of Pathology, St. Jude Medical Center, Fullerton, CA  
Wendy L. Frankel, MD, FCAP

Department of Pathology, Ohio State University Medical Center, Columbus, OH  
John Jessup, MD

Division of Cancer Treatment and Diagnosis, National Cancer Institute, Bethesda, MD  
Sanjay Kakar, MD, FCAP

Department of Pathology, University of California San Francisco and the Veterans Affairs Medical Center, San Francisco, CA

Bruce Minsky, MD

Department of Radiation Oncology, University of Chicago, Chicago, IL

Raouf Nakhleh, MD, FCAP

Department of Pathology, Mayo Clinic, Jacksonville, FL

Carolyn C. Compton, MD, PhD, FCAP†

Office of Biorepositories and Biospecimen Research, National Cancer Institute, Bethesda, MD

For the Members of the Cancer Committee, College of American Pathologists

\*denotes primary author. † denotes senior author. All other contributing authors are listed alphabetically.

**Previous contributors:** Randall G. Lee, MD; Leslie H. Sobin, MD; Donald Antonioli, MD; Harvey Goldman, MD; Rodger C. Haggitt, MD; Robert V. P. Hutter, MD; Klaus Lewin, MD; Pablo Ross, MD; Heidrun Rotterdam, MD; Stuart Spechler, MD; Christopher Willett, MD; Donald E. Henson, MD

## Gastrointestinal • Esophagus and Esophagogastric Junction

### Esophagus 3.0.0.0

© 2009 College of American Pathologists (CAP). All rights reserved.

The College does not permit reproduction of any substantial portion of these protocols without its written authorization. The College hereby authorizes use of these protocols by physicians and other health care providers in reporting on surgical specimens, in teaching, and in carrying out medical research for nonprofit purposes. This authorization does not extend to reproduction or other use of any substantial portion of these protocols for commercial purposes without the written consent of the College.

The CAP also authorizes physicians and other health care practitioners to make modified versions of the Protocols solely for their individual use in reporting on surgical specimens for individual patients, teaching, and carrying out medical research for non-profit purposes.

The CAP further authorizes the following uses by physicians and other health care practitioners, in reporting on surgical specimens for individual patients, in teaching, and in carrying out medical research for non-profit purposes: (1) **Dictation** from the original or modified protocols for the purposes of creating a text-based patient record on paper, or in a word processing document; (2) **Copying** from the original or modified protocols into a text-based patient record on paper, or in a word processing document; (3) The use of a **computerized system** for items (1) and (2), provided that the Protocol data is stored intact as a single text-based document, and is not stored as multiple discrete data fields.

Other than uses (1), (2), and (3) above, the CAP does not authorize any use of the Protocols in electronic medical records systems, pathology informatics systems, cancer registry computer systems, computerized databases, mappings between coding works, or any computerized system without a written license from CAP. Applications for such a license should be addressed to the SNOMED Terminology Solutions division of the CAP.

Any public dissemination of the original or modified Protocols is prohibited without a written license from the CAP.

The College of American Pathologists offers these protocols to assist pathologists in providing clinically useful and relevant information when reporting results of surgical specimen examinations of surgical specimens. The College regards the reporting elements in the "Surgical Pathology Cancer Case Summary (Checklist)" portion of the protocols as essential elements of the pathology report. However, the manner in which these elements are reported is at the discretion of each specific pathologist, taking into account clinician preferences, institutional policies, and individual practice.

The College developed these protocols as an educational tool to assist pathologists in the useful reporting of relevant information. It did not issue the protocols for use in litigation, reimbursement, or other contexts. Nevertheless, the College recognizes that the protocols might be used by hospitals, attorneys, payers, and others. Indeed, effective January 1, 2004, the Commission on Cancer of the American College of Surgeons mandated the use of the checklist elements of the protocols as part of its Cancer Program Standards for Approved Cancer Programs. Therefore, it becomes even more important for pathologists to familiarize themselves with these documents. At the same time, the College cautions that use of the protocols other than for their intended educational purpose may involve additional considerations that are beyond the scope of this document.

The inclusion of a product name or service in a CAP publication should not be construed as an endorsement of such product or service, nor is failure to include the name of a product or service to be construed as disapproval.

## **CAP Esophagus Protocol Revision History**

---

### **Version Code**

The definition of the version code can be found at [www.cap.org/cancerprotocols](http://www.cap.org/cancerprotocols).

**Version:** Esophagus 3.0.0.0

### **Summary of Changes**

No changes have been made since the October 2009 release.

## **Surgical Pathology Cancer Case Summary (Checklist)**

---

Protocol web posting date: October 2009

### **ESOPHAGUS: Endoscopic Resection, Esophagectomy, or Esophagogastrectomy (Note A)**

Select a single response unless otherwise indicated.

#### **Specimen (select all that apply)**

- Esophagus
- Proximal stomach
- Other (specify): \_\_\_\_\_
- Not specified

#### **Procedure**

- Endoscopic resection
- Esophagectomy
- Esophagogastrectomy
- Other (specify): \_\_\_\_\_
- Not specified

#### **Tumor Site (select all that apply) (Note B)**

- Cervical (proximal) esophagus
- Midesophagus
- \*  Upper thoracic esophagus
- \*  Midthoracic esophagus
- Distal esophagus (lower thoracic esophagus)
- Esophagogastric junction (EGJ)
- Proximal stomach and esophagogastric junction
- Other (specify): \_\_\_\_\_
- Not specified

#### **Relationship of Tumor to Esophagogastric Junction (Note B)**

- Tumor is entirely located within the tubular esophagus and does not involve the esophagogastric junction
- Tumor midpoint lies in the distal esophagus *and* tumor involves the esophagogastric junction
- Tumor midpoint is located at the esophagogastric junction
- Tumor midpoint lies in the proximal stomach or cardia *and* tumor involves the esophagogastric junction
- Not specified
- Cannot be assessed

Distance of tumor center from esophagogastric junction (specify, if applicable): \_\_\_\_ cm

\* Data elements with asterisks are not required. However, these elements may be clinically important but are not yet validated or regularly used in patient management.

**Tumor Size**

Greatest dimension: \_\_\_ cm

\*Additional dimensions: \_\_\_ x \_\_\_ cm

\_\_\_ Cannot be determined (see "Comment")

**Histologic Type (Note C)**

\_\_\_ Squamous cell carcinoma

\_\_\_ Adenocarcinoma

\_\_\_ Adenosquamous carcinoma

\_\_\_ Small cell carcinoma

\_\_\_ Undifferentiated carcinoma

\_\_\_ Other (specify): \_\_\_\_\_

\_\_\_ Carcinoma, type cannot be determined

**Histologic Grade (Note D)**

\_\_\_ Not applicable

\_\_\_ GX: Cannot be assessed

\_\_\_ G1: Well differentiated

\_\_\_ G2: Moderately differentiated

\_\_\_ G3: Poorly differentiated

\_\_\_ G4: Undifferentiated

**Microscopic Tumor Extension (Note E)**

\_\_\_ Cannot be assessed

\_\_\_ No evidence of primary tumor

\_\_\_ High-grade dysplasia (carcinoma in situ)

\_\_\_ Tumor invades lamina propria

\_\_\_ Tumor invades muscularis mucosae

\_\_\_ Tumor invades submucosa

\_\_\_ Tumor invades muscularis propria

\_\_\_ Tumor invades through the muscularis propria into the periesophageal soft tissue (adventitia)

\_\_\_ Tumor directly invades adjacent structures (specify): \_\_\_\_\_

**Margins (select all that apply) (Note F)**Proximal Margin

\_\_\_ Cannot be assessed

\_\_\_ Uninvolved by invasive carcinoma

\_\_\_ Involved by invasive carcinoma

\_\_\_ Uninvolved by dysplasia

\_\_\_ Involved by dysplasia

\_\_\_ Squamous dysplasia

\_\_\_ Intestinal metaplasia (Barrett's esophagus) with dysplasia

\_\_\_ Involved by intestinal metaplasia (Barrett's esophagus) without dysplasia

\* Data elements with asterisks are not required. However, these elements may be clinically important but are not yet validated or regularly used in patient management.

Distal Margin

- Cannot be assessed  
 Uninvolved by invasive carcinoma  
 Involved by invasive carcinoma  
 Uninvolved by dysplasia  
 Involved by dysplasia  
      Squamous dysplasia  
      Intestinal metaplasia (Barrett's esophagus) with dysplasia  
 Involved by intestinal metaplasia (Barrett's esophagus) without dysplasia

Circumferential (Adventitial) Margin (esophagectomy or esophagogastrectomy specimens) or Deep Margin (endoscopic resection specimens)

- Cannot be assessed  
 Uninvolved by invasive carcinoma  
 Involved by invasive carcinoma

If all margins uninvolved by invasive carcinoma:

Distance of invasive carcinoma from closest margin: \_\_\_ cm

Specify margin: \_\_\_\_\_

**Treatment Effect (applicable to carcinomas treated with neoadjuvant therapy) (select all that apply) (Note G)**

- No prior treatment  
 Present  
     \*  No residual tumor (complete response, grade 0)  
     \*  Marked response (grade 1, minimal residual cancer)  
     \*  Moderate response (grade 2)  
 No definite response identified (grade 3, poor or no response)  
 Treatment history not known

**Lymph-Vascular Invasion**

- Not identified  
 Present  
 Indeterminate

**\*Perineural Invasion**

- \*  Not identified  
 \*  Present  
 \*  Indeterminate

**Pathologic Staging (pTNM) (Note H)**

TNM Descriptors (required only if applicable) (select all that apply)

- m (multiple primary tumors)  
 r (recurrent)  
 y (posttreatment)

\* Data elements with asterisks are not required. However, these elements may be clinically important but are not yet validated or regularly used in patient management.

Primary Tumor (pT)

- pTX: Cannot be assessed  
 pT0: No evidence of primary tumor  
 pTis: High-grade dysplasia  
 pT1: Tumor invades lamina propria, muscularis mucosae, or submucosa  
 pT1a: Tumor invades lamina propria or muscularis mucosae  
 pT1b: Tumor invades submucosa  
 pT2: Tumor invades muscularis propria  
 pT3: Tumor invades adventitia  
 pT4: Tumor invades adjacent structures (specify): \_\_\_\_\_  
 pT4a: Resectable tumor invading pleura, pericardium, or diaphragm  
 \*pT4b: Unresectable tumor invading other adjacent structures, such as aorta, vertebral body, trachea, etc

Regional Lymph Nodes (pN) (Note I)

- pNX: Cannot be assessed  
 pN0: No regional lymph node metastasis  
 pN1: Regional lymph node metastasis involving 1 to 2 nodes  
 pN2: 3 to 6 nodes involved  
 pN3: 7 or more nodes involved  
 Specify: Number examined: \_\_\_\_  
               Number involved: \_\_\_\_

Distant Metastasis (pM)

- Not applicable  
 pM1: Distant metastasis  
               \*Specify site(s), if known: \_\_\_\_\_

**Additional Pathologic Findings (select all that apply) (Note J)**

- None identified  
 Intestinal metaplasia (Barrett's esophagus)  
 Dysplasia  
      Low grade  
      High grade  
 \* Esophagitis (type): \_\_\_\_\_  
 \* Gastritis (type): \_\_\_\_\_  
 \* Other (specify): \_\_\_\_\_

**\*Ancillary Studies**

\*Specify: \_\_\_\_\_

**\*Clinical History (select all that apply) (Note J)**

- \* Barrett's esophagus  
 \* Other (specify): \_\_\_\_\_  
 \* Not known

**\*Comment(s)**

\* Data elements with asterisks are not required. However, these elements may be clinically important but are not yet validated or regularly used in patient management.

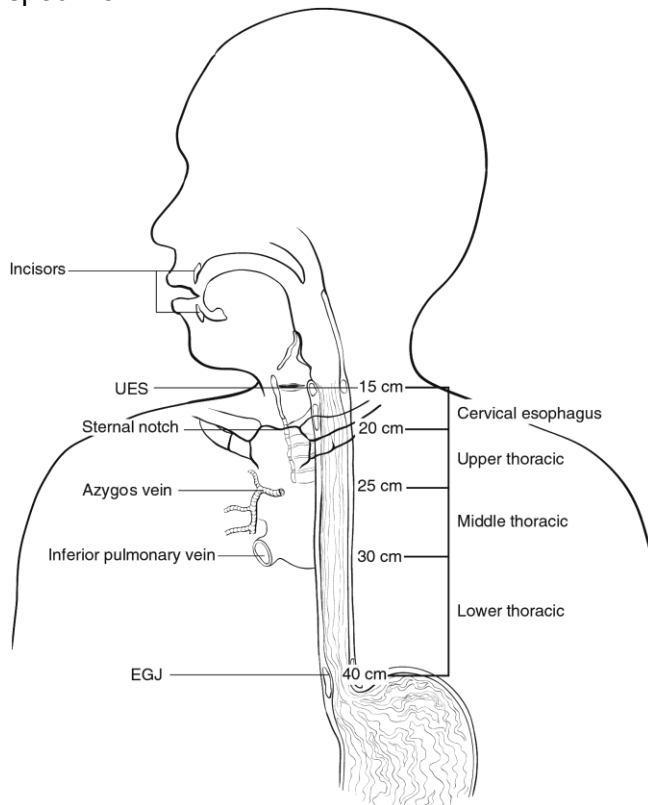
## Explanatory Notes

### A. Application

This protocol applies to all carcinomas arising in the esophagus and to carcinomas involving the esophagogastric junction (EGJ), including tumors that cross the EGJ but are predominantly located in the proximal stomach. Lymphomas, well-differentiated neuroendocrine tumors (carcinoid tumors), and sarcomas are also not included (separate TNM staging systems<sup>1</sup> and CAP protocols apply).

### B. Location

The location of the tumor in the esophagus (cervical, upper thoracic, midthoracic, lower thoracic, abdominal) and with respect to the macroscopic EGJ (defined as where the tubular esophagus meets the stomach, as measured from the top of the gastric folds) should be noted whenever possible (Figure 1). The macroscopic EGJ often does not correspond to the junction of esophageal squamous mucosa and columnar mucosa because of the common finding in esophageal resection specimens of glandular mucosa involving the distal esophagus. Because anatomic divisions of the esophagus are defined by anatomic boundaries and relationships to other structures,<sup>1</sup> it may not be possible for the pathologist to determine exact tumor location from the resection specimen.



**Figure 1.** Anatomic subdivisions of the esophagus. From Edge et al.<sup>1</sup> Used with permission of the American Joint Committee on Cancer (AJCC), Chicago, Illinois. The original source for this material is the *AJCC Cancer Staging Manual*, 7th edition (2009) published by Springer Science and Business Media LLC, [www.springerlink.com](http://www.springerlink.com).



For tumors involving the esophagogastric junction, specific observations should be recorded in an attempt to establish the exact site of origin of the tumor. The EGJ is defined as the junction of the tubular esophagus and the stomach, irrespective of the type of epithelial lining of the esophagus. The pathologist should record the maximum longitudinal dimension of the tumor mass, the distance of the tumor midpoint from the EGJ, and the relative proportions of the tumor mass located in the esophagus and in the stomach.

Tumors involving the EGJ are classified for purposes of staging as esophageal carcinomas.<sup>1</sup> Although the nature of these tumors (gastric versus esophageal) has been controversial<sup>2,3</sup> (reviewed by Carneiro and Chaves<sup>4</sup>), recent data support their classification as esophageal carcinomas.<sup>1</sup> The World Health Organization (WHO) defines esophageal tumors as those located entirely above the EGJ and proximal gastric tumors as those located entirely below the EGJ.<sup>5</sup> Tumors crossing the EGJ are classified as EGJ tumors. An alternative system proposed by Siewart and colleagues divides adenocarcinomas involving the EGJ into three categories, based upon location of the midpoint of the tumor<sup>6</sup>:

Type I: adenocarcinoma of the distal esophagus, with or without infiltration of the EGJ from above

Type II: true carcinoma of the gastric cardia, arising from the cardiac epithelium or short segments with intestinal metaplasia at the EGJ

Type III: subcardial gastric carcinoma, which infiltrates the EGJ and distal esophagus from below

Application of the Siewart system is complicated by lack of consensus as to the definition and nature of the gastric cardia, with some investigators regarding it as a normal anatomic finding,<sup>7</sup> and others as a metaplastic response to injury from esophagogastric reflux.<sup>2,4</sup>

### C. Histologic Type

For consistency in reporting, the histologic classification proposed by the WHO is recommended.<sup>5</sup> However, this protocol does not preclude the use of other systems of classification or histologic types.

Worldwide, squamous cell carcinoma continues to predominate as the most common histologic type, but numerous population-based studies document the increasing incidence of adenocarcinoma of the esophagus and EGJ in Western countries.<sup>8</sup> More than 50% of esophageal carcinomas diagnosed in the United States since 1900 are adenocarcinomas. Other subtypes, such as adenoid cystic carcinoma and mucoepidermoid carcinoma, which resemble their counterparts arising in salivary gland, are rarely encountered.

The revised TNM staging system for esophageal carcinomas incorporates tumor grade and histologic type in the stage groupings (see Note H). Mixed histologic types, such as adenosquamous carcinomas, are staged using the squamous cell carcinoma stage grouping.<sup>1</sup>

### WHO Classification of Carcinoma of the Esophagus

Squamous cell carcinoma

Verrucous (squamous) carcinoma  
Spindle cell (squamous) carcinoma  
Adenocarcinoma  
Adenosquamous carcinoma  
Mucoepidermoid carcinoma<sup>#</sup>  
Adenoid cystic carcinoma<sup>#</sup>  
Small cell carcinoma<sup>#</sup>  
Undifferentiated carcinoma<sup>#</sup>  
Others

<sup>#</sup>These types are not generally graded.

The term “carcinoma, NOS (not otherwise specified)” is not part of the WHO classification.

#### **D. Histologic Grade**

The histologic grades for esophageal squamous cell carcinomas are as follows:

Grade X Grade cannot be assessed  
Grade 1 Well differentiated  
Grade 2 Moderately differentiated  
Grade 3 Poorly differentiated

If there are variations in the differentiation within the tumor, the highest (least favorable) grade is recorded. In general, mucoepidermoid carcinoma and adenoid cystic carcinoma of the esophagus are not amenable to grading.

For adenocarcinomas, a suggested grading system based on the proportion of the tumor that is composed of glands is as follows:

Grade X Grade cannot be assessed  
Grade 1 Well differentiated (greater than 95% of tumor composed of glands)  
Grade 2 Moderately differentiated (50% to 95% of tumor composed of glands)  
Grade 3 Poorly differentiated (49% or less of tumor composed of glands)

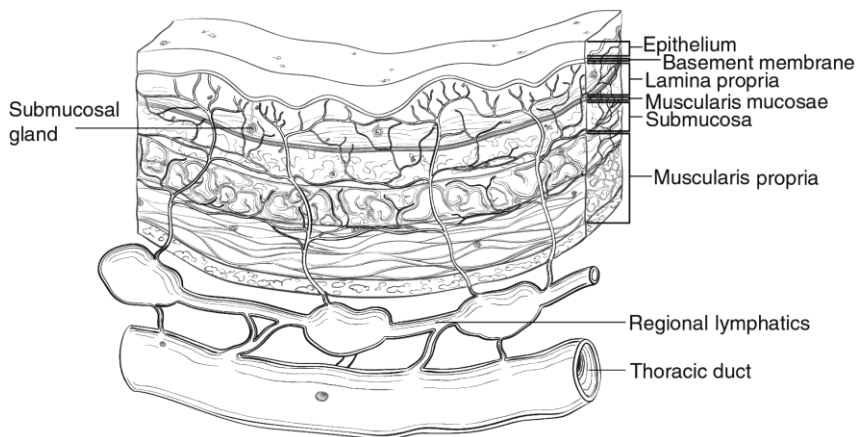
Undifferentiated tumors cannot be categorized as squamous cell carcinoma or adenocarcinoma (or other) type. They are classified as "undifferentiated carcinomas" in the WHO classification of tumor types (see above) and may be assigned grade 4. Small cell carcinomas are not typically graded but are high-grade tumors and would correspond to grade 4.

The revised TNM staging system for esophageal carcinomas incorporates tumor grade and histologic type in the stage groupings (see Note H). For purposes of staging, grade 4 carcinomas (undifferentiated carcinomas) are staged as grade 3 squamous cell carcinomas.<sup>1</sup> Grade X tumors are grouped as grade 1 carcinomas.

#### **E. Tumor Extension**

For purposes of data reporting, Barrett’s esophagus with high-grade dysplasia in an esophageal resection specimen is reported as “carcinoma in situ.” The term “carcinoma in situ” is not widely applied to glandular neoplastic lesions in the gastrointestinal tract

but is retained for tumor registry reporting purposes as specified by law in many states. Invasion of the lamina propria may be difficult to assess for glandular neoplasms in the esophagus. The muscularis mucosae (Figure 2) is commonly duplicated and thickened in Barrett's esophagus; invasion of this layer should not be misinterpreted as invasion of the muscularis propria.<sup>9</sup> It should be noted that the muscularis mucosae varies in organization from relatively sparse bundles of smooth muscle in the cervical esophagus to a thickened reticulated network in the distal esophagus.<sup>10</sup>



**Figure 2.** Microscopic anatomy of the esophagus. From Edge et al.<sup>1</sup> Used with permission of the American Joint Committee on Cancer (AJCC), Chicago, Illinois. The original source for this material is the *AJCC Cancer Staging Manual*, 7th edition (2009) published by Springer Science and Business Media LLC, www.springerlink.com.

## F. Margins

Margins include the proximal, distal, and radial margins. The radial margin represents the adventitial soft tissue margin closest to the deepest penetration of tumor. Sections to evaluate the proximal and distal resections margins can be obtained in 2 orientations: (1) en face sections parallel to the margin, or (2) longitudinal sections perpendicular to the margin. Depending on the closeness of the tumor to the margin, select the orientation(s) that will most clearly demonstrate the status of the margin. The distance from the tumor edge to the closest resection margin(s) should be measured. Proximal and distal resection margins should be evaluated for Barrett's esophagus and for squamous and glandular dysplasia. It may be helpful to mark the margin(s) closest to the tumor with ink. Margins marked by ink should be so designated in the macroscopic description.

## G. Treatment Effect

Response of tumor to previous chemotherapy or radiation therapy should be reported. Although grading systems for tumor response have not been established, in general, three-category systems provide good interobserver reproducibility.<sup>11</sup> The following system is suggested:

Description	Tumor Regression Grade
No viable cancer cells	0 (Complete response)
Single cells or small groups of cancer cells	1 (Moderate response)

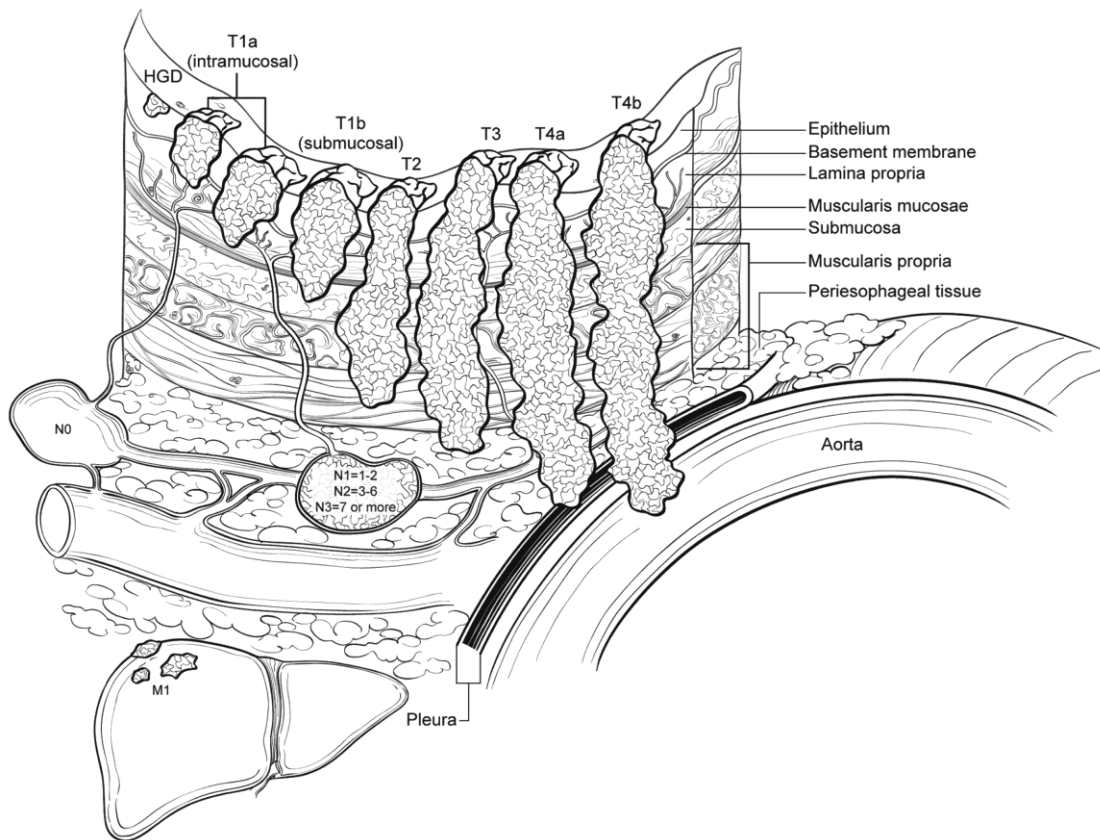
Residual cancer outgrown by fibrosis	2 (Minimal response)
Minimal or no tumor kill; extensive residual cancer	3 (Poor response)

Sizable pools of acellular mucin may be present after chemoradiation but should not be interpreted as representing residual tumor.

This protocol does not preclude the use of other systems for assessment of tumor response.<sup>12-14</sup>

## H. TNM and Anatomic Stage/Prognostic Groupings

The TNM staging system for esophageal carcinoma of the American Joint Committee on Cancer (AJCC) and the International Union Against Cancer (UICC) is recommended (Figure 3).<sup>1</sup>



**Figure 3.** T, N, and M classifications for esophageal carcinoma. From Edge et al.<sup>1</sup> Used with permission of the American Joint Committee on Cancer (AJCC), Chicago, Illinois. The original source for this material is the *AJCC Cancer Staging Manual*, 7th edition (2009) published by Springer Science and Business Media LLC, www.springerlink.com.

According to AJCC/UICC convention, the designation “T” refers to a primary tumor that has not been previously treated. The symbol “p” refers to the pathologic classification of the TNM, as opposed to the clinical classification, and is based on gross and microscopic examination. pT entails a resection of the primary tumor or biopsy adequate to evaluate the highest pT category, pN entails removal of nodes adequate to validate lymph node metastasis, and pM implies microscopic examination of distant lesions.

Clinical classification (cTNM) is usually carried out by the referring physician before treatment during initial evaluation of the patient or when pathologic classification is not possible.

Pathologic staging is usually performed after surgical resection of the primary tumor. Pathologic staging depends on pathologic documentation of the anatomic extent of disease, whether or not the primary tumor has been completely removed. If a biopsied tumor is not resected for any reason (eg, when technically infeasible) and if the highest T and N categories or the M1 category of the tumor can be confirmed microscopically, the criteria for pathologic classification and staging have been satisfied without total removal of the primary cancer.

### TNM Descriptors

For identification of special cases of TNM or pTNM classifications, the “m” suffix and “y,” “r,” and “a” prefixes are used. Although they do not affect the stage grouping, they indicate cases needing separate analysis.

The “m” suffix indicates the presence of multiple primary tumors in a single site and is recorded in parentheses: pT(m)NM.

The “y” prefix indicates those cases in which classification is performed during or after initial multimodality therapy (ie, neoadjuvant chemotherapy, radiation therapy, or both chemotherapy and radiation therapy). The cTNM or pTNM category is identified by a “y” prefix. The ycTNM or ypTNM categorizes the extent of tumor actually present at the time of that examination. The “y” categorization is not an estimate of tumor before multimodality therapy (ie, before initiation of neoadjuvant therapy).

The “r” prefix indicates a recurrent tumor when staged after a documented disease-free interval and is identified by the “r” prefix: rTNM.

The “a” prefix designates the stage determined at autopsy: aTNM.

### N Category Considerations

A mediastinal lymphadenectomy specimen will ordinarily include 7 or more regional lymph nodes.

### Stage Groupings: Squamous Cell Carcinoma

Stage	T	N	M	G	Location
Stage 0	Tis	N0	M0 <sup>#</sup>	1	Any
Stage IA	T1	N0	M0	1	Any
Stage IB	T1	N0	M0	2 or 3	Any
	T2 or T3	N0	M0	1	Lower
Stage IIA	T2 or T3	N0	M0	1	Upper, middle
	T2 or T3	N0	M0	2 or 3	Lower
Stage IIB	T2 or T3	N0	M0	2 or 3	Upper, middle
	T1 or T2	N1	M0	Any	Any
Stage IIIA	T1 or T2	N2	M0	Any	Any
	T3	N1	M0	Any	Any
	T4a	N0	M0	Any	Any
Stage IIIB	T3	N2	M0	Any	Any

**Background Documentation****Gastrointestinal • Esophagus/Esophagogastric Junction**

Esophagus 3.0.0.0

Stage IIIC	T4a	N1 or N2	M0	Any	Any
	T4b	Any	M0	Any	Any
	Any	N3	M0	Any	Any
Stage IV	Any T	Any N	M1	Any	Any

# M0 is defined as no distant metastasis.

**Stage Grouping: Adenocarcinoma**

<b>Stage</b>	<b>T</b>	<b>N</b>	<b>M</b>	<b>G</b>
Stage 0	Tis (HGD <sup>#</sup> )	N0	M0	1
Stage IA	T1	N0	M0	1 or 2
Stage IB	T1	N0	M0	3
	T2	N0	M0	1 to 2
Stage IIA	T2	N0	M0	3
Stage IIB	T3	N0	M0	Any
	T1 or T2	N1	M0	Any
Stage IIIA	T1 or T2	N2	M0	Any
	T3	N1	M0	Any
	T4a	N0	M0	Any
Stage IIIB	T3	N2	M0	Any
Stage IIIC	T4a	N1 or N2	M0	Any
	T4b	Any	M0	Any
	Any	N3	M0	Any
Stage IV	Any T	Any N	M1	Any

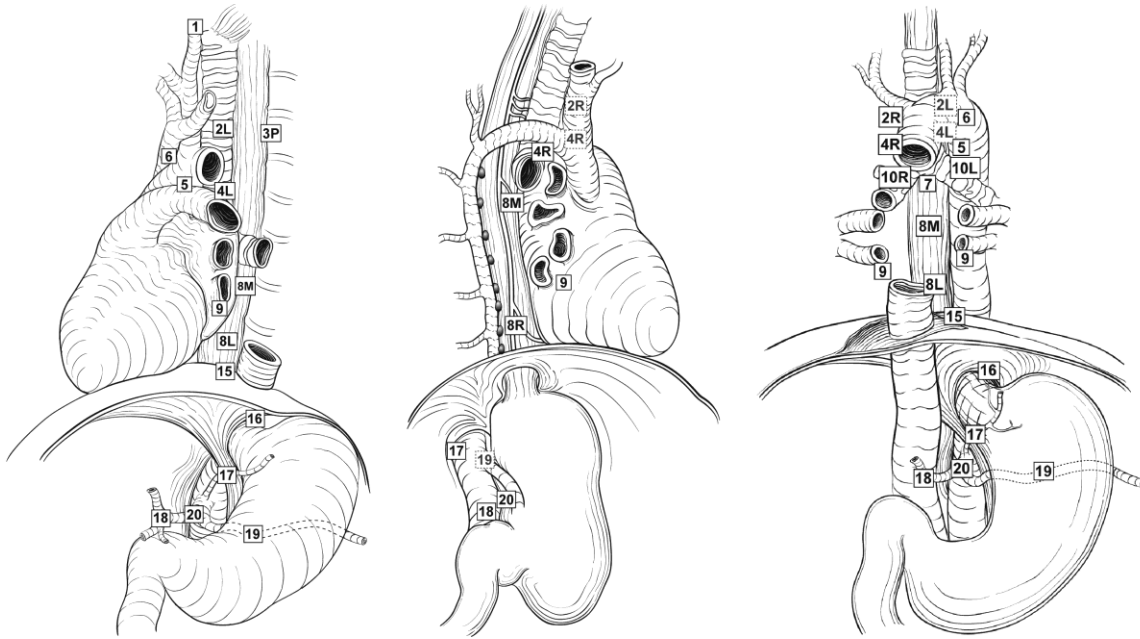
# HGD, high-grade dysplasia.

**Additional Descriptors**Lymph-Vascular Invasion

Lymph-vascular invasion (LVI) indicates whether microscopic lymph-vascular invasion is identified in the pathology report. LVI includes lymphatic invasion, vascular invasion, or lymph-vascular invasion. By AJCC/UICC convention, LVI does not affect the T category indicating local extent of tumor unless specifically included in the definition of a T category.

**I. Regional Lymph Nodes**

Regional lymph nodes (Figure 4) extend from periesophageal cervical nodes for the cervical esophagus to celiac lymph nodes for the distal esophagus.<sup>1</sup> Number of involved lymph nodes has consistently emerged as a prognostic indicator on multivariate analysis.<sup>15,16</sup> Extranodal extension may identify a subset of node-positive patients with a particularly poor prognosis.<sup>17</sup>



**Figure 4.** Regional lymph nodes of the esophagus. From Edge et al.<sup>1</sup> Used with permission of the American Joint Committee on Cancer (AJCC), Chicago, Illinois. The original source for this material is the *AJCC Cancer Staging Manual*, 7th edition (2009) published by Springer Science and Business Media LLC, [www.springerlink.com](http://www.springerlink.com).

## J. Additional Findings

Most esophageal adenocarcinomas develop in the setting of Barrett's esophagus, which is defined as alteration of the mucosal lining of the esophagus from the normal squamous epithelium to metaplastic columnar epithelium in response to esophagogastric reflux. Although in some cases the columnar epithelium may resemble gastric oxyntic or cardiac mucosa, only the specialized columnar epithelium with goblet cells is considered to carry significant risk of cancer and is designated as Barrett's esophagus for diagnostic purposes.

## References

1. Edge SB, Byrd DR, Carducci MA, Compton CC, eds. *AJCC Cancer Staging Manual*. 7th ed. New York, NY: Springer; 2009.
2. Chandrasoma P, Wickramasinghe K, Ma Y, DeMeester T. Adenocarcinomas of the distal esophagus and "gastric cardia" are predominantly esophageal carcinomas. *Am J Surg Pathol*. 2007;31(4):569-575.
3. Mattioli S, Ruffato A, Di Simone MP, et al. Immunopathological patterns of the stomach in adenocarcinoma of the esophagus, cardia, and gastric antrum: gastric profiles in Siewert type I and II tumors. *Ann Thorac Surg*. 2007;83(5):1814-1819.
4. Carneiro F, Chaves P. Pathologic risk factors of adenocarcinoma of the gastric cardia and gastroesophageal junction. *Surg Oncol Clin North Am*. 2006;15(4):697-714.
5. Hamilton SR, Aaltonen LA. *Pathology and Genetics of Tumours of the Digestive System*. Lyon, France: IARC Press; 2000. *World Health Organization Classification of Tumours*. Vol 2.

6. Feith M, Stein HJ, Siewert JR. Adenocarcinoma of the esophagogastric junction: surgical therapy based on 1602 consecutive resected patients. *Surg Oncol Clin North Am.* 2006;15(4):751-764.
7. Glickman JN, Fox V, Antonioli DA, Wang HH, Odze RD. Morphology of the cardia and significance of carditis in pediatric patients. *Am J Surg Pathol.* 2002;26(8):1032-1039.
8. Keeney S, Bauer TL. Epidemiology of adenocarcinoma of the esophagogastric junction. *Surg Oncol Clin North Am.* 2006;15(4):687-696.
9. Abraham SC, Krasinskas AM, Correa AM, et al. Duplication of the muscularis mucosae in Barrett esophagus: an underrecognized feature and its implication for staging of adenocarcinoma. *Am J Surg Pathol.* 2007;31(11):1719-1725.
10. Nagai K, Noguchi T, Hashimoto T, Uchida Y, Shimada T. The organization of the lamina muscularis mucosae in the human esophagus. *Arch Histol Cytol.* 2003;66(3):281-288.
11. Ryan R, Gibbons D, Hyland JM, et al. Pathological response following long-course neoadjuvant chemoradiotherapy for locally advanced rectal cancer. *Histopathology.* 2005;47(2):141-146.
12. Brucher BLD, Becker K, Lordick F, et al. The clinical impact of histopathologic response assessment by residual tumor cell quantification in esophageal squamous cell carcinomas. *Cancer.* May 15 2006;106(10):2119-2127.
13. Hermann RM, Horstmann O, Haller F, et al. Histomorphological tumor regression grading of esophageal carcinoma after neoadjuvant radiochemotherapy: which score to use? *Dis Esoph.* 2006;19(5):329-334.
14. Wu T-T, Chirieac LR, Abraham SC, et al. Excellent interobserver agreement on grading the extent of residual carcinoma after preoperative chemoradiation in esophageal and esophagogastric junction carcinoma: a reliable predictor for patient outcome. *Am J Surg Pathol.* 2007;31(1):58-64.
15. Christein JD, Hollinger EF, Millikan KW. Prognostic factors associated with resectable carcinoma of the esophagus. *Am Surg.* 2002;68(3):258-262; discussion 262-263.
16. Gu Y, Swisher SG, Ajani JA, et al. The number of lymph nodes with metastasis predicts survival in patients with esophageal or esophagogastric junction adenocarcinoma who receive preoperative chemoradiation. *Cancer.* 2006;106(5):1017-1025.
17. Lagarde SM, ten Kate FJW, de Boer DJ, Busch ORC, Obertop H, van Lanschot JJB. Extracapsular lymph node involvement in node-positive patients with adenocarcinoma of the distal esophagus or gastroesophageal junction. *Am J Surg Pathol.* 2006;30(2):171-176.