

# Protocol for the Examination of Specimens from Patients with Carcinoma of the Gallbladder

**Protocol applies to all invasive carcinomas of the gallbladder and cystic duct, including those showing focal endocrine differentiation. Well-differentiated neuroendocrine neoplasms (carcinoid tumors) are not included.**

---

**Based on AJCC/UICC TNM, 7th edition**

Protocol web posting date: October 2009

## Procedures

- Cholecystectomy
- Cholecystectomy with Partial Hepatectomy
- Cholecystectomy with Lymph Node Dissection

## Authors

Kay Washington, MD, PhD, FCAP\*

Department of Pathology, Vanderbilt University Medical Center, Nashville, TN

Jordan Berlin, MD

Department of Medicine, Vanderbilt University Medical Center, Nashville, TN

Philip Branton, MD, FCAP

Department of Pathology, Inova Fairfax Hospital, Falls Church, VA

Lawrence J. Burgart, MD, FCAP

Allina Laboratories, Abbott Northwestern Hospital, Minneapolis, MN

David K. Carter, MD, FCAP

Department of Pathology, St. Mary's/Duluth Clinic Health System, Duluth, MN

Carolyn C. Compton, MD, PhD, FCAP

Office of Biorepositories and Biospecimen Research, National Cancer Institute, Bethesda, MD

Patrick Fitzgibbons, MD, FCAP

Department of Pathology, St. Jude Medical Center, Fullerton, CA

Wendy L. Frankel, MD, FCAP

Department of Pathology, Ohio State University Medical Center, Columbus, OH

John Jessup, MD

Division of Cancer Treatment and Diagnosis, National Cancer Institute, Bethesda, MD

Sanjay Kakar, MD, FCAP

Department of Pathology, University of California San Francisco and the Veterans Affairs Medical Center, San Francisco, CA

Bruce Minsky, MD

Department of Radiation Oncology, University of Chicago, Chicago, IL

Raouf Nakhleh, MD, FCAP

Department of Pathology, Mayo Clinic, Jacksonville, FL

Jean-Nicolas Vauthey, MD†

Department of Surgical Oncology, University of Texas MD Anderson Cancer Center, Houston, TX

For the Members of the Cancer Committee, College of American Pathologists

\*denotes primary author. † denotes senior author. All other contributing authors are listed alphabetically.

**Previous contributors:** Donald E. Henson, MD; Jorge Albores-Saavedra, MD

© 2009 College of American Pathologists (CAP). All rights reserved.

The College does not permit reproduction of any substantial portion of these protocols without its written authorization. The College hereby authorizes use of these protocols by physicians and other health care providers in reporting on surgical specimens, in teaching, and in carrying out medical research for nonprofit purposes. This authorization does not extend to reproduction or other use of any substantial portion of these protocols for commercial purposes without the written consent of the College.

The CAP also authorizes physicians and other health care practitioners to make modified versions of the Protocols solely for their individual use in reporting on surgical specimens for individual patients, teaching, and carrying out medical research for non-profit purposes.

The CAP further authorizes the following uses by physicians and other health care practitioners, in reporting on surgical specimens for individual patients, in teaching, and in carrying out medical research for non-profit purposes: (1) **Dictation** from the original or modified protocols for the purposes of creating a text-based patient record on paper, or in a word processing document; (2) **Copying** from the original or modified protocols into a text-based patient record on paper, or in a word processing document; (3) The use of a **computerized system** for items (1) and (2), provided that the Protocol data is stored intact as a single text-based document, and is not stored as multiple discrete data fields.

Other than uses (1), (2), and (3) above, the CAP does not authorize any use of the Protocols in electronic medical records systems, pathology informatics systems, cancer registry computer systems, computerized databases, mappings between coding works, or any computerized system without a written license from CAP. Applications for such a license should be addressed to the SNOMED Terminology Solutions division of the CAP.

Any public dissemination of the original or modified Protocols is prohibited without a written license from the CAP.

The College of American Pathologists offers these protocols to assist pathologists in providing clinically useful and relevant information when reporting results of surgical specimen examinations of surgical specimens. The College regards the reporting elements in the "Surgical Pathology Cancer Case Summary (Checklist)" portion of the protocols as essential elements of the pathology report. However, the manner in which these elements are reported is at the discretion of each specific pathologist, taking into account clinician preferences, institutional policies, and individual practice.

The College developed these protocols as an educational tool to assist pathologists in the useful reporting of relevant information. It did not issue the protocols for use in litigation, reimbursement, or other contexts. Nevertheless, the College recognizes that the protocols might be used by hospitals, attorneys, payers, and others. Indeed, effective January 1, 2004, the Commission on Cancer of the American College of Surgeons mandated the use of the checklist elements of the protocols as part of its Cancer Program Standards for Approved Cancer Programs. Therefore, it becomes even more important for pathologists to familiarize themselves with these documents. At the same time, the College cautions that use of the protocols other than for their intended educational purpose may involve additional considerations that are beyond the scope of this document.

The inclusion of a product name or service in a CAP publication should not be construed as an endorsement of such product or service, nor is failure to include the name of a product or service to be construed as disapproval.

## **CAP Gallbladder Protocol Revision History**

---

### **Version Code**

The definition of the version code can be found at [www.cap.org/cancerprotocols](http://www.cap.org/cancerprotocols).

**Version:** Gallbladder 3.0.0.0

### **Summary of Changes**

No changes have been made since the October 2009 release.

## **Surgical Pathology Cancer Case Summary (Checklist)**

---

Protocol web posting date: October 2009

### **GALLBLADDER: Resection/Cholecystectomy**

Select a single response unless otherwise indicated.

#### **Specimen (select all that apply)**

- Gallbladder
- Liver
- Extrahepatic bile duct
- Other (specify): \_\_\_\_\_
- Not specified

#### **Procedure (Note A)**

- Simple cholecystectomy (laparoscopic or open)
- Radical cholecystectomy (with liver resection and lymphadenectomy)
- Other (specify): \_\_\_\_\_
- Not specified

#### **Tumor Site (select all that apply)**

- Fundus
- Body
- Neck
- Cystic Duct
- Free peritoneal side of gallbladder
- Hepatic side of gallbladder
- Cannot be determined
- Other, specify \_\_\_\_\_
- Not specified

#### **Tumor Size**

Greatest dimension: \_\_\_\_ cm

\*Additional dimensions: \_\_\_\_ x \_\_\_\_ cm

Cannot be determined (see Comment)

\* Data elements with asterisks are not required. However, these elements may be clinically important but are not yet validated or regularly used in patient management.

**Histologic Type (Note B)**

- Adenocarcinoma
- Papillary adenocarcinoma
- Adenocarcinoma, intestinal type
- Mucinous adenocarcinoma
- Signet-ring cell carcinoma
- Clear cell carcinoma
- Squamous cell carcinoma
- Adenosquamous carcinoma
- Small cell carcinoma
- Undifferentiated carcinoma
- Other (specify): \_\_\_\_\_
- Carcinoma, not otherwise specified

**Histologic Grade (Note C)**

- Not applicable
- GX: Cannot be assessed
- G1: Well differentiated
- G2: Moderately differentiated
- G3: Poorly differentiated
- G4: Undifferentiated
- Other (specify): \_\_\_\_\_

**Microscopic Tumor Extension**

- Tumor invades lamina propria
- Tumor invades muscle layer
- Tumor invades perimuscular connective tissue; no extension beyond serosa or into liver
- Tumor perforates serosa (visceral peritoneum)
- Tumor directly invades the liver
- Tumor directly invades extrahepatic bile ducts
- Tumor directly invades other adjacent organ or structure, such as the stomach, duodenum, colon, pancreas, or omentum (specify): \_\_\_\_\_

**Margins (select all that apply) (Note D)**

- Cannot be assessed
- Margins uninvolved by invasive carcinoma
  - Distance of invasive carcinoma from closest margin: \_\_\_\_ mm
  - Specify margin: \_\_\_\_\_
- Margins involved by invasive carcinoma
  - Specify margin(s): \_\_\_\_\_
- Cystic duct margin uninvolved by intramucosal carcinoma
- Cystic duct margin involved by intramucosal carcinoma

**\*Lymph-Vascular Invasion (Note E)**

- \*  Not identified
- \*  Present
- \*  Indeterminate

\* Data elements with asterisks are not required. However, these elements may be clinically important but are not yet validated or regularly used in patient management.

**\*Perineural Invasion (Note F)**

- \* \_\_\_ Not identified
- \* \_\_\_ Present
- \* \_\_\_ Indeterminate

**Pathologic Staging (pTNM) (Note G)**

TNM Descriptors (required only if applicable) (select all that apply)

- \_\_\_ m (multiple primary tumors)
- \_\_\_ r (recurrent)
- \_\_\_ y (post-treatment)

Primary Tumor (pT)

- \_\_\_ pTX: Cannot be assessed
- \_\_\_ pT0: No evidence of primary tumor
- \_\_\_ pTis: Carcinoma in situ
- pT1: Tumor invades lamina propria or muscular layer
  - \_\_\_ pT1a: Tumor invades lamina propria
  - \_\_\_ pT1b: Tumor invades muscle layer
- \_\_\_ pT2: Tumor invades perimuscular connective tissue; no extension beyond serosa or into liver
- \_\_\_ pT3: Tumor perforates serosa (visceral peritoneum) and/or directly invades the liver and/or one other adjacent organ or structure, such as the stomach, duodenum, colon, pancreas, omentum, or extrahepatic bile ducts
- \_\_\_ pT4: Tumor invades main portal vein or hepatic artery or invades 2 or more extrahepatic organs or structures

Regional Lymph Nodes (pN)

- \_\_\_ pNX: Cannot be assessed
  - \_\_\_ pN0: No regional lymph node metastasis
  - \_\_\_ pN1: Metastases to nodes along the cystic duct, common bile duct, hepatic artery, and/or portal vein
  - \_\_\_ pN2: Metastases to periaortic, pericaval, superior mesentery artery, and/or celiac artery lymph nodes
- Specify: Number examined \_\_\_  
Number involved \_\_\_

Distant Metastasis (pM)

- \_\_\_ Not applicable
- \_\_\_ pM1: Distant metastasis
  - \*Specify site(s), if known: \_\_\_\_\_

\* Data elements with asterisks are not required. However, these elements may be clinically important but are not yet validated or regularly used in patient management.

**\*Additional Pathologic Findings (select all that apply) (Note H)**

- \*  None identified
- \*  Dysplasia/adenoma
- \*  Cholelithiasis
- \*  Chronic cholecystitis
- \*  Acute cholecystitis
- \*  Intestinal metaplasia
- \*  Diffuse calcification (porcelain gallbladder)
- \*  Other (specify): \_\_\_\_\_

**\*Ancillary Studies**

- \* Specify: \_\_\_\_\_
- \*  Not performed

**\*Clinical History (select all that apply) (Note I)**

- \*  Cholelithiasis
- \*  Primary sclerosing cholangitis
- \*  Other (specify): \_\_\_\_\_

**\*Comment(s)**

\* Data elements with asterisks are not required. However, these elements may be clinically important but are not yet validated or regularly used in patient management.

## Explanatory Notes

---

### A. Occult Carcinomas in Cholecystectomy Specimens

Occasionally carcinoma is found in gallbladders removed by laparoscopic surgery. Not recognized clinically or by imaging techniques, tumor is discovered during pathologic evaluation of the resected specimen. In this setting, tumor spillage with seeding along the laparoscopic tract or intra-abdominal dissemination may be a major complication of the procedure, with port site recurrences reported in up to 17% of such cases.<sup>1</sup> If dysplasia is found in such specimens, multiple sections should be examined to exclude invasive cancer.

### B. Histologic Type

For consistency in reporting, the histologic classification proposed by the World Health Organization (WHO), shown below, is recommended.<sup>2</sup> However, this protocol does not preclude use of other systems of classification or histologic types.

#### WHO Classification of Gallbladder Carcinomas

Adenocarcinoma<sup>#</sup>

Papillary adenocarcinoma<sup>##</sup>

Adenocarcinoma, intestinal type

Adenocarcinoma, gastric foveolar type

Mucinous adenocarcinoma<sup>###</sup>

Clear cell adenocarcinoma<sup>##</sup>

Signet-ring cell carcinoma<sup>^</sup>

Adenosquamous carcinoma

Squamous cell carcinoma

Small cell carcinoma<sup>^^</sup>

Large cell neuroendocrine carcinoma

Undifferentiated carcinoma<sup>^^</sup>

Biliary cystadenocarcinoma

<sup>#</sup>Many adenocarcinomas contain scattered neuroendocrine cells. These tumors should not be considered neuroendocrine carcinomas.

<sup>##</sup>These histologic types are not usually graded (see below).

<sup>###</sup>A mucocele may be mistaken for a mucinous carcinoma. Mucoceles often contain macrophages that have engulfed mucin (muciphages). Consequently, these macrophages may resemble signet-ring cells. Neoplastic signet-ring cells are cytokeratin-positive and carcinoembryonic antigen (CEA)-positive, whereas muciphages do not stain for these markers.

<sup>^</sup>By convention, signet-ring cell carcinomas are assigned grade 3 (see below).

<sup>^^</sup>Small cell carcinomas and undifferentiated (histologic type) carcinomas are assigned grade 4 (see below). Small cell carcinomas should be specifically reported because they may cause endocrine syndromes. In addition, small cell carcinomas and undifferentiated carcinomas are, by definition, high grade (grade 4), an adverse prognostic factor.<sup>3</sup>

**C. Histologic Grade**

The following grading system, based on the extent of glandular formation in the tumor, is suggested:

Grade X	Grade cannot be assessed
Grade 1	Well differentiated (greater than 95% of tumor composed of glands)
Grade 2	Moderately differentiated (50% to 95% of tumor composed of glands)
Grade 3	Poorly differentiated (49% or less of tumor composed of glands)

Grade 4 carcinomas are classified as undifferentiated carcinomas (histologic type) by the WHO classification<sup>2</sup> (see above).

Although tumor stage is probably the most important prognostic factor for patient outcome, histologic grade, especially for poorly differentiated and infiltrative tumors, also has an impact on survival.<sup>4</sup>

**D. Margins**

Complete surgical resection with negative margins remains the most effective therapy for gallbladder cancer, with 5-year survival advantages of 30% for patients with negative margins compared with those with microscopic residual disease.<sup>5</sup>

**E. Venous/Lymphatic Vessel Invasion**

Blood vessel and/or lymphatic invasion has been reported to be an adverse prognostic feature in some but not all studies.<sup>6-8</sup>

**F. Perineural Invasion**

Perineural invasion by neoplastic cells is very common in gallbladder carcinoma and has been identified as an adverse prognostic factor in some but not all studies.<sup>6,9,10</sup>

Perineural invasion has been associated with spread of carcinoma beyond the gallbladder to involve the biliary tree.<sup>11</sup> A diagnostic pitfall may occur in cases of adenomyomatous hyperplasia, because the ductal structures of adenomyomatous hyperplasia may invade perineural spaces.<sup>12</sup>

**G. TNM and Anatomic Stage/Prognostic Grouping**

Surgical resection is the most effective therapy for gallbladder carcinomas, and the best estimation of prognosis is related to the anatomic extent (stage) of disease at the time of resection. In particular, lymph node metastases are predictors of poorer outcome.<sup>13,14</sup>

The TNM staging system for carcinomas of the gallbladder of the American Joint Committee on Cancer (AJCC) and the International Union Against Cancer (UICC) is recommended by the protocol and shown below.<sup>15</sup> The TNM system does not apply to carcinoid tumors or to sarcomas. Carcinomas of the gallbladder are staged according to their depth of penetration into the wall and extension to adjacent organs, and the extent of invasion correlates inversely with survival.<sup>16</sup>

According to AJCC/UICC convention, the designation “T” refers to a primary tumor that has not been previously treated. The symbol “p” refers to the pathologic classification of the TNM, as opposed to the clinical classification, and is based on gross and microscopic examination. pT entails a resection of the primary tumor or biopsy adequate to evaluate the highest pT category, pN entails removal of nodes adequate to validate lymph node metastasis, and pM implies microscopic examination of distant lesions. Clinical classification (cTNM) is usually carried out by the referring physician before treatment during initial evaluation of the patient or when pathologic classification is not possible.

Pathologic staging is usually performed after surgical resection of the primary tumor. Pathologic staging depends on pathologic documentation of the anatomic extent of disease, whether or not the primary tumor has been completely removed. If a biopsied tumor is not resected for any reason (eg, when technically infeasible) and if the highest T and N categories or the M1 category of the tumor can be confirmed microscopically, the criteria for pathologic classification and staging have been satisfied without total removal of the primary cancer.

### **TNM Descriptors**

For identification of special cases of TNM or pTNM classifications, the “m” suffix and “y,” “r,” and “a” prefixes are used. Although they do not affect the stage grouping, they indicate cases needing separate analysis.

The “m” suffix indicates the presence of multiple primary tumors in a single site and is recorded in parentheses: pT(m)NM.

The “y” prefix indicates those cases in which classification is performed during or after initial multimodality therapy (ie, neoadjuvant chemotherapy, radiation therapy, or both chemotherapy and radiation therapy). The cTNM or pTNM category is identified by a “y” prefix. The ycTNM or ypTNM categorizes the extent of tumor actually present at the time of that examination. The “y” categorization is not an estimate of tumor before multimodality therapy (ie, before initiation of neoadjuvant therapy).

The “r” prefix indicates a recurrent tumor when staged after a documented disease-free interval and is identified by the “r” prefix: rTNM.

The “a” prefix designates the stage determined at autopsy: aTNM.

### **T Category Considerations**

pTis. For gallbladder carcinomas, "carcinoma in situ" (pTis) as a staging term includes neoplastic cells cytologically indistinguishable from invasive carcinoma but confined within the glandular basement membrane.<sup>3</sup> Separation of high-grade dysplasia from carcinoma in situ is subjective, and because morphologic criteria are ill defined, subject to interobserver variability. The term “carcinoma in situ” is not widely applied to glandular neoplastic lesions in the gastrointestinal tract but is retained for tumor registry reporting purposes as specified by law in many states. Noninvasive gallbladder carcinomas with a papillary growth pattern are classified as pTis.

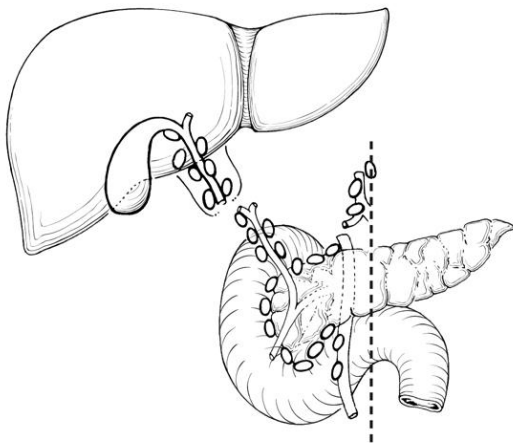
Because carcinoma in situ may be multifocal, cases of carcinoma in situ should be studied by multiple sections or by the “Swiss role” method in order to exclude invasive cancer in other areas of the gallbladder. Dysplasia of the gallbladder mucosa is often confused with the reactive change due to inflammation or repair.

Involvement of Rokitansky-Aschoff (RA) sinuses. Distinguishing extension of dysplastic epithelium into RA sinuses from invasive carcinoma may be difficult. A recent study of 49 cases of gallbladder carcinoma extending into or originating from RA sinuses lists the following useful criteria for in situ carcinoma: connection of epithelial invaginations to the luminal surface, normal biliary epithelium admixed with neoplastic epithelium, inspissated bile in long dilated spaces, and lack of invasion of smooth muscle bundles.<sup>17</sup>

### N Category Considerations

The frequency of nodal involvement depends on the depth of invasion into the gallbladder wall by the primary tumor. In general, carcinomas of the gallbladder spread from involvement of the hepatoduodenal ligament toward the nodes around the head of the pancreas. The cystic and pericholedochal nodes are the key stations for spread toward the peripancreatic nodes. Lymph flows through the pericholedochal nodes to these other regional nodes. Most often, the tumor initially metastasizes to the pericholedochal lymph nodes.

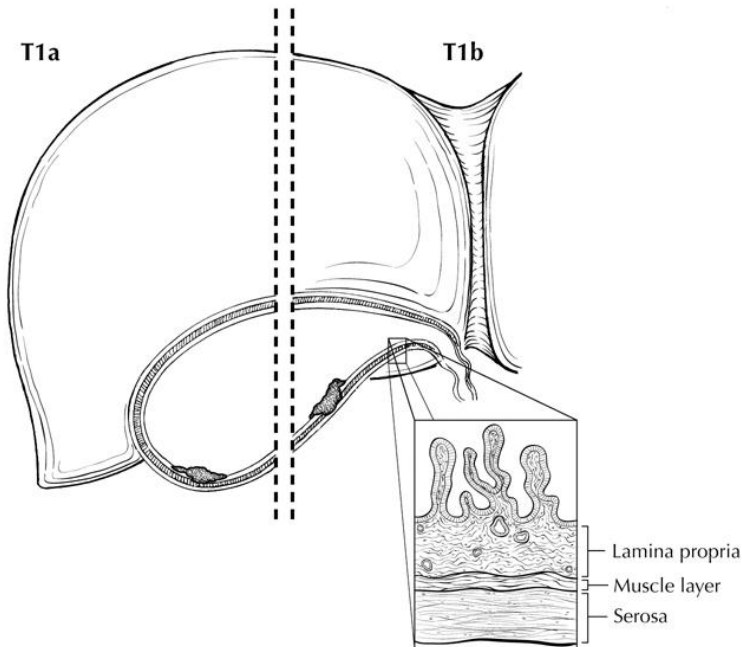
The regional lymph nodes of the gallbladder include the cystic duct, pericholedochal, hilar (ie, in the hepatoduodenal ligament), peripancreatic (head only), periduodenal, periportal, celiac, and superior mesenteric lymph nodes (Figure 1). The hilar nodes include those along the inferior vena cava, hepatic artery, portal vein, and hepatic pedicle. Peripancreatic nodes located along the body and tail of the pancreas are sites of distant metastasis.



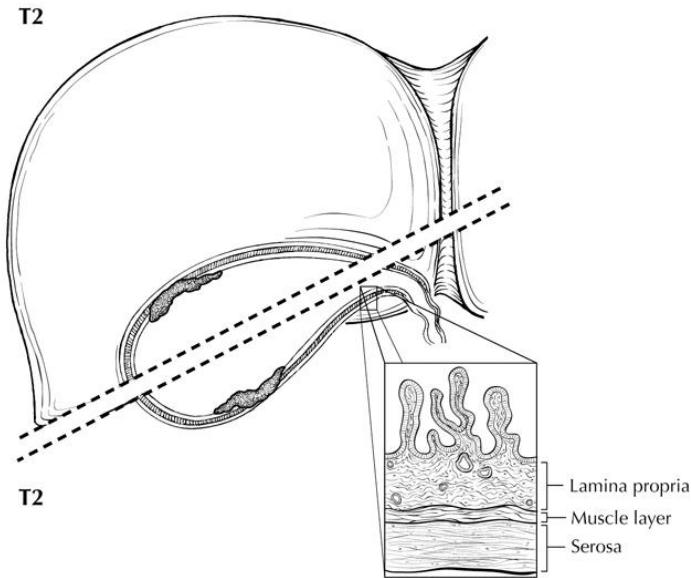
**Figure 1.** Regional lymph nodes of the gallbladder. From: Greene FL, Compton, CC, Fritz AG, et al, eds. *AJCC Cancer Staging Atlas*. New York: Springer; 2006. Copyright © American Joint Committee on Cancer. Used with permission.

Although it has been suggested that micrometastases detected by immunohistochemical studies for cytokeratin are associated with poor outcome in

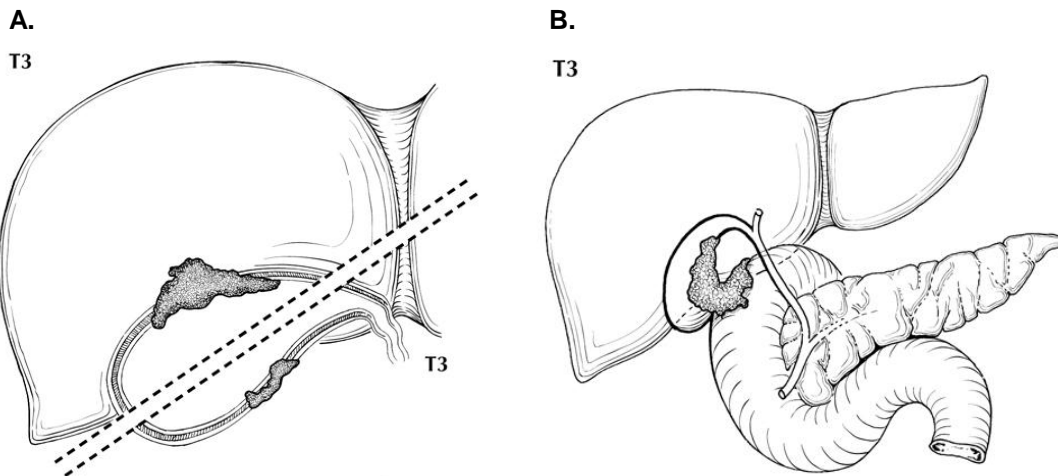
gallbladder carcinomas,<sup>9</sup> such studies are few in number and remain unvalidated by larger series. Routine assessment of regional lymph nodes is limited to conventional pathologic techniques (gross assessment and histologic examination), and data are currently insufficient to recommend special measures to detect micrometastasis or isolated tumor cells. Thus, neither multiple levels of paraffin blocks nor the use of special/ancillary techniques, such as immunohistochemistry, are recommended for routine examination of regional lymph nodes.<sup>13</sup>



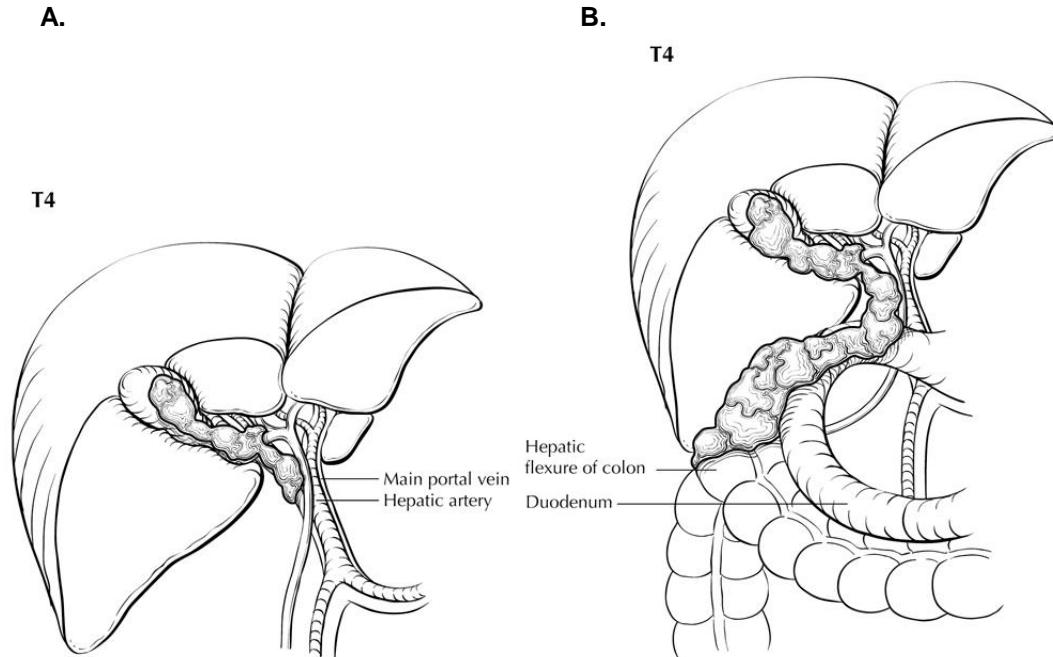
**Figure 2.** T1a is defined as tumor invading lamina propria; T1b is defined as tumor invading muscle layer. From: Greene FL, Compton, CC, Fritz AG, et al, eds. *AJCC Cancer Staging Atlas*. New York: Springer; 2006. Copyright © American Joint Committee on Cancer. Used with permission.



**Figure 3.** Two views of T2: tumor invading perimuscular connective tissue (below dotted line) and tumor with no extension beyond serosa or into the liver (above dotted line). From: Greene FL, Compton, CC, Fritz AG, et al, eds. *AJCC Cancer Staging Atlas*. New York: Springer; 2006. Copyright © American Joint Committee on Cancer. Used with permission.



**Figure 4.** Two views of T3. A. tumor perforating the serosa (visceral peritoneum) (below dotted line) and/or directly invading the liver (above dotted line). B. T3 may also be defined as tumor invading one other adjacent organ or structure, such as the duodenum (illustrated). From: Greene FL, Compton, CC, Fritz AG, et al, eds. *AJCC Cancer Staging Atlas*. New York: Springer; 2006. Copyright © American Joint Committee on Cancer. Used with permission.



**Figure 5.** A. T4 is defined as tumor invading the main portal vein or hepatic artery (illustrated) or invading two or more extrahepatic organs or structures. B. T4 invading two or more extrahepatic organs or structures (here, invading colon and duodenum). From: Greene FL, Compton, CC, Fritz AG, et al, eds. *AJCC Cancer Staging Atlas*. New York: Springer; 2006. Copyright © American Joint Committee on Cancer. Used with permission.

#### Primary Tumor (T) (Figures 2 through 5)

- TX Primary tumor cannot be assessed
- T0 No evidence of primary tumor
- Tis Carcinoma in situ
- T1 Tumor invades lamina propria or muscular layer
- T1a Tumor invades lamina propria
- T1b Tumor invades muscular layer
- T2 Tumor invades perimuscular connective tissue; no extension beyond serosa or into liver
- T3 Tumor perforates the serosa (visceral peritoneum) and/or directly invades the liver and/or one other adjacent organ or structure, such as the stomach, duodenum, colon, pancreas, omentum, or extrahepatic bile ducts
- T4 Tumor invades main portal vein or hepatic artery or invades two or more extrahepatic organs or structures

#### Regional Lymph Nodes (N)

- NX Regional lymph nodes cannot be assessed
- N0 No regional lymph node metastases
- N1 Metastases to nodes along the cystic duct, common bile duct, hepatic artery, and/or portal vein
- N2 Metastases to periaortic, pericaaval, superior mesentery artery, and/or celiac artery lymph nodes

#### Distant Metastasis (M)

M0	No distant metastasis
M1	Distant metastasis

**Stage Groupings**

Stage 0	Tis	N0	M0
Stage I	T1	N0	M0
Stage II	T2	N0	M0
Stage IIIA	T3	N0	M0
Stage IIIB	T1, T2, or T3	N1	M0
Stage IVA	T4	Any N	M0
Stage IVB	Any T	N 2	Any M
	Any T	Any N	M1

**Vessel Invasion**

According to AJCC/UICC convention, vessel invasion (lymphatic or venous) does not affect the T category indicating local extent of tumor unless specifically included in the definition of a T category.

**H. Additional Pathologic Findings**

Other common lesions include chronic cholecystitis and various types of metaplasia, such as squamous, pyloric gland, and intestinal metaplasia. Occasionally changes consistent with inflammatory bowel disease are found in the gallbladder. Diffuse calcification of the gallbladder (porcelain gallbladder) has historically been associated with gallbladder carcinoma, although this relationship has been questioned.<sup>18,19</sup> Recent publications indicate that selective mucosal calcification, rather than diffuse intramural calcification, may be more closely associated with gallbladder cancer.<sup>18</sup>

The presence or absence of stones should be reported. Gallbladder cancer occurring in the absence of stones may result from an anomalous choledocho-pancreatic junction or from an association with chronic inflammatory bowel disease.

**I. Clinical History**

In addition to long-standing cholelithiasis and chronic cholecystitis, other conditions causing chronic inflammation may predispose to gallbladder carcinoma. Gallbladders from patients with primary sclerosing cholangitis (PSC) should be carefully examined for dysplasias, reported in 37% of cases, and adenocarcinoma, reported in 14% of cases in a recent study examining gallbladders from patients with PSC undergoing orthotopic liver transplantation.<sup>20</sup>

**References**

1. Giuliante F, Ardito F, Vellone M, Clemente G, Nuzzo G. Port-site excisions for gallbladder cancer incidentally found after laparoscopic cholecystectomy. *Am J Surg.* 2006;191(1):114-116.
2. Albores-Saavedra J, Scoazec JC, Wittekind C, et al. Tumours of the gallbladder and extrahepatic bile ducts. In: Hamilton SR, Aaltonen LA, eds. *World Health Organization Classification of Tumours: Pathology and Genetics of Tumours of the Digestive System.* Lyon, France: IARC Press; 2000:203-218.

3. Albores-Saavedra J, Henson DE, Klimstra DS. *Tumors of the Gallbladder, Extrahepatic Bile Duct, and Ampulla of Vater*. Vol Fascicle 27. Third Series ed. Washington, DC: Armed Forces Institute of Pathology; 2000.
4. Park JS, Yoon DS, Kim KS, et al. Actual recurrence patterns and risk factors influencing recurrence after curative resection with stage II gallbladder carcinoma. *J Gastrointest Surg*. 2007;11(5):631-637.
5. Balachandran P, Agarwal S, Krishnani N, et al. Predictors of long-term survival in patients with gallbladder cancer. *J Gastrointest Surg*. 2006;10(6):848-854.
6. Aramaki M, Matsumoto T, Shibata K, et al. Factors influencing recurrence after surgical treatment for T2 gallbladder carcinoma. *Hepatogastroenterology*. Nov-Dec 2004;51(60):1609-1611.
7. Chijiwa K, Yamaguchi K, Tanaka M. Clinicopathologic differences between long-term and short-term postoperative survivors with advanced gallbladder carcinoma. *World J Surg*. 1997;21(1):98-102.
8. Yamaguchi K, Chijiwa K, Saiki S, et al. Retrospective analysis of 70 operations for gallbladder carcinoma. *Br J Surg*. 1997;84(2):200-204.
9. Sasaki E, Nagino M, Ebata T, et al. Immunohistochemically demonstrated lymph node micrometastasis and prognosis in patients with gallbladder carcinoma. *Ann Surg*. 2006;244(1):99-105.
10. Yamaguchi R, Nagino M, Oda K, Kamiya J, Uesaka K, Nimura Y. Perineural invasion has a negative impact on survival of patients with gallbladder carcinoma. *Br J Surg*. 2002;89(9):1130-1136.
11. Yamaguchi K, Chijiwa K, Saiki S, Shimizu S, Takashima M, Tanaka M. Carcinoma of the extrahepatic bile duct: mode of spread and its prognostic implications. *Hepatogastroenterology*. 1997;44(17):1256-1261.
12. Albores-Saavedra J, Henson DE. Adenomyomatous hyperplasia of the gallbladder with perineural invasion. *Arch Pathol Lab Med*. 1995;119:1173-1176.
13. de Aretxabala X, Roa I, Burgos L, et al. Gallbladder cancer: an analysis of a series of 139 patients with invasion restricted to the subserosal layer. *J Gastrointest Surg*. 2006;10(2):186-192.
14. Endo I, Shimada H, Tanabe M, et al. Prognostic significance of the number of positive lymph nodes in gallbladder cancer. *J Gastrointest Surg*. 2006;10(7):999-1007.
15. Edge SB, Byrd DR, Carducci MA, Compton CC, eds. *AJCC Cancer Staging Manual*. 7th ed. New York, NY: Springer; 2009.
16. Sasaki R, Uesugi N, Itabashi H, et al. Clinicopathological study of depth of subserosal invasion in patients with pT2 gallbladder carcinoma. *J Surg Oncol*. Nov 1 2005;92(2):83-88.
17. Albores-Saavedra J, Shukla D, Carrick K, Henson DE. In situ and invasive adenocarcinomas of the gallbladder extending into or arising from Rokitansky-Aschoff sinuses: a clinicopathologic study of 49 cases. *Am J Surg Pathol*. 2004;28(5):621-628.
18. Stephen AE, Berger DL. Carcinoma in the porcelain gallbladder: a relationship revisited. *Surgery*. Jun 2001;129(6):699-703.
19. Towfigh S, McFadden DW, Cortina GR, et al. Porcelain gallbladder is not associated with gallbladder carcinoma. *Am Surg*. 2001;67(1):7-10.
20. Lewis JT, Talwalkar JA, Rosen CB, Smyrk TC, Abraham SC. Prevalence and risk factors for gallbladder neoplasia in patients with primary sclerosing

cholangitis: evidence for a metaplasia-dysplasia-carcinoma sequence. *Am J Surg Pathol.* 2007;31(6):907-913.