

Protocol for the Examination of Specimens from Patients with Hepatocellular Carcinoma

Cholangiocarcinoma, mixed hepatocellular-cholangiocarcinoma, and hepatoblastoma are not included.

Based on AJCC/UICC TNM, 7th edition

Protocol web posting date: October 2009

Procedure

- Hepatic Resection, Partial or Complete

Authors

Kay Washington, MD, PhD, FCAP*

Department of Pathology, Vanderbilt University Medical Center, Nashville, TN

Jordan Berlin, MD

Department of Medicine, Vanderbilt University Medical Center, Nashville, TN

Philip Branton, MD, FCAP

Department of Pathology, Inova Fairfax Hospital, Falls Church, VA

Lawrence J. Burgart, MD, FCAP

Allina Laboratories, Abbott Northwestern Hospital, Minneapolis, MN

David K. Carter, MD, FCAP

Department of Pathology, St. Mary's/Duluth Clinic Health System, Duluth, MN

Carolyn C. Compton, MD, PhD, FCAP

Office of Biorepositories and Biospecimen Research, National Cancer Institute, Bethesda, MD

Wendy L. Frankel, MD, FCAP

Department of Pathology, Ohio State University Medical Center, Columbus, OH

John Jessup, MD

Division of Cancer Treatment and Diagnosis, National Cancer Institute, Bethesda, MD

Sanjay Kakar, MD, FCAP

Department of Pathology, University of California San Francisco and the Veterans Affairs Medical Center, San Francisco, CA

Bruce Minsky, MD

Department of Radiation Oncology, University of Chicago, Chicago, IL

Raouf Nakhleh, MD, FCAP

Department of Pathology, Mayo Clinic, Jacksonville, FL

Jean-Nicolas Vauthey, MD†

Department of Surgical Oncology, University of Texas MD Anderson Cancer Center, Houston, TX

For the Members of the Cancer Committee, College of American Pathologists

*denotes primary author. † denotes senior author. All other contributing authors are listed alphabetically.

Previous contributors: John R. Craig, MD; Alberto M. Marchevsky, MD; Stephen G. Ruby, MD; Gregorio Chejfec, MD; John A. Payne, MD; Jerome B. Taxy, MD; Christopher Willett, MD; James Williams, MD

© 2009 College of American Pathologists (CAP). All rights reserved.

The College does not permit reproduction of any substantial portion of these protocols without its written authorization. The College hereby authorizes use of these protocols by physicians and other health care providers in reporting on surgical specimens, in teaching, and in carrying out medical research for nonprofit purposes. This authorization does not extend to reproduction or other use of any substantial portion of these protocols for commercial purposes without the written consent of the College.

The CAP also authorizes physicians and other health care practitioners to make modified versions of the Protocols solely for their individual use in reporting on surgical specimens for individual patients, teaching, and carrying out medical research for non-profit purposes.

The CAP further authorizes the following uses by physicians and other health care practitioners, in reporting on surgical specimens for individual patients, in teaching, and in carrying out medical research for non-profit purposes: (1) **Dictation** from the original or modified protocols for the purposes of creating a text-based patient record on paper, or in a word processing document; (2) **Copying** from the original or modified protocols into a text-based patient record on paper, or in a word processing document; (3) The use of a **computerized system** for items (1) and (2), provided that the Protocol data is stored intact as a single text-based document, and is not stored as multiple discrete data fields.

Other than uses (1), (2), and (3) above, the CAP does not authorize any use of the Protocols in electronic medical records systems, pathology informatics systems, cancer registry computer systems, computerized databases, mappings between coding works, or any computerized system without a written license from CAP. Applications for such a license should be addressed to the SNOMED Terminology Solutions division of the CAP.

Any public dissemination of the original or modified Protocols is prohibited without a written license from the CAP.

The College of American Pathologists offers these protocols to assist pathologists in providing clinically useful and relevant information when reporting results of surgical specimen examinations of surgical specimens. The College regards the reporting elements in the "Surgical Pathology Cancer Case Summary (Checklist)" portion of the protocols as essential elements of the pathology report. However, the manner in which these elements are reported is at the discretion of each specific pathologist, taking into account clinician preferences, institutional policies, and individual practice.

The College developed these protocols as an educational tool to assist pathologists in the useful reporting of relevant information. It did not issue the protocols for use in litigation, reimbursement, or other contexts. Nevertheless, the College recognizes that the protocols might be used by hospitals, attorneys, payers, and others. Indeed, effective January 1, 2004, the Commission on Cancer of the American College of Surgeons mandated the use of the checklist elements of the protocols as part of its Cancer Program Standards for Approved Cancer Programs. Therefore, it becomes even more important for pathologists to familiarize themselves with these documents. At the same time, the College cautions that use of the protocols other than for their intended educational purpose may involve additional considerations that are beyond the scope of this document.

The inclusion of a product name or service in a CAP publication should not be construed as an endorsement of such product or service, nor is failure to include the name of a product or service to be construed as disapproval.

CAP Hepatocellular Carcinoma Protocol Revision History

Version Code

The definition of the version code can be found at www.cap.org/cancerprotocols.

Version: Hepatocellular 3.0.0.0

Summary of Changes

No changes have been made since the October 2009 release.

Surgical Pathology Cancer Case Summary (Checklist)

Protocol web posting date: October 2009

HEPATOCELLULAR CARCINOMA: Hepatic Resection (Note A)

Select a single response unless otherwise indicated.

Specimen (select all that apply)

- Liver
 Gallbladder
 Other (specify): _____
 Not specified

Procedure (select all that apply) (Note B)

- Wedge resection
 Partial hepatectomy
 * Major hepatectomy (3 segments or more)
 * Minor hepatectomy (less than 3 segments)
 Total hepatectomy
 Other (specify): _____
 Not specified

Tumor Size

- Greatest dimension: ___ cm
 *Additional dimensions: ___ x ___ cm
 Cannot be determined (see Comment)

Tumor Focality (Note B)

- Solitary (specify location): _____
 Multiple (specify location): _____

Histologic Type (Note C)

- Hepatocellular carcinoma
 Fibrolamellar hepatocellular carcinoma
 Undifferentiated carcinoma
 Other (specify): _____
 Carcinoma, type cannot be determined

Histologic Grade (Note D)

- Not applicable
 GX: Cannot be assessed
 GI: Well differentiated
 GII: Moderately differentiated
 GIII: Poorly differentiated
 GIV: Undifferentiated/anaplastic
 Other (specify): _____

* Data elements with asterisks are not required. However, these elements may be clinically important but are not yet validated or regularly used in patient management.

Tumor Extension (select all that apply)

- Tumor confined to liver
 Tumor involves a major branch of the portal vein
 Tumor involves 1 or more hepatic vein(s)
 Tumor involves visceral peritoneum
 Tumor directly invades gallbladder
 Tumor directly invades other adjacent organs (specify): _____

Margins (select all that apply) (Note E)Parenchymal Margin

- Cannot be assessed
 Uninvolved by invasive carcinoma
 Distance of invasive carcinoma from closest margin: ____ mm
 Specify margin: _____
 Involved by invasive carcinoma

Other Margin

- Specify margin: _____
 Cannot be assessed
 Uninvolved by invasive carcinoma
 Involved by invasive carcinoma

Lymph-Vascular Invasion (Note F)Macroscopic Venous (Large Vessel) Invasion (V)

- Not identified
 Present
 Indeterminate

Microscopic (Small Vessel) Invasion (L)

- Not identified
 Present
 Indeterminate

***Perineural Invasion**

- * Not identified
 * Present
 * Indeterminate

Pathologic Staging (pTNM) (Note G)TNM Descriptors (required only if applicable) (select all that apply)

- m (multiple primary tumors)
 r (recurrent)
 y (post-treatment)

* Data elements with asterisks are not required. However, these elements may be clinically important but are not yet validated or regularly used in patient management.

Primary Tumor (pT)

- pTX: Cannot be assessed
 pT0: No evidence of primary tumor
 pT1: Solitary tumor without vascular invasion
 pT2: Solitary tumor with vascular invasion or multiple tumors none more than 5 cm
 pT3a: Multiple tumors more than 5 cm
 pT3b: Single tumor or multiple tumors of any size involving a major branch of the portal vein or hepatic veins
 pT4: Tumor(s) with direct invasion of adjacent organs other than the gallbladder or with perforation of visceral peritoneum

Regional Lymph Nodes (pN)

- pNX: Cannot be assessed
 pN0: No regional lymph node metastasis
 pN1: Regional lymph node metastasis
 Specify: Number examined: ____
 Number involved: ____

Distant Metastasis (pM)

- Not applicable
 pM1: Distant metastasis
 *Specify site(s), if known: _____

***Additional Pathologic Findings (select all that apply) (Note H)**

*Fibrosis score:

- * Cirrhosis/severe fibrosis (Ishak score 5-6) (F1)
 * None to moderate fibrosis (Ishak score 0-4) (F2)

- * Hepatocellular dysplasia
 * Low-grade dysplastic nodule
 * High-grade dysplastic nodule

* Steatosis* Iron overload* Chronic hepatitis (specify etiology): _____* Other (specify): _____* None identified***Ancillary Studies**

*Specify: _____

* Data elements with asterisks are not required. However, these elements may be clinically important but are not yet validated or regularly used in patient management.

***Clinical History (select all that apply) (Note I)**

- * Cirrhosis
- * Hepatitis C infection
- * Hepatitis B infection
- * Alcoholic liver disease
- * Obesity
- * Hereditary hemochromatosis
- * Other (specify): _____
- * Not known

***Comment(s)**

* Data elements with asterisks are not required. However, these elements may be clinically important but are not yet validated or regularly used in patient management.

Explanatory Notes

A. Application

This protocol applies only to hepatic resection specimens containing hepatocellular carcinoma. Carcinomas of the intrahepatic bile ducts (cholangiocarcinomas) are now staged using a separate TNM system.¹

B. Tumor Location, Focality and Histologic Sampling

The segmental anatomy of the liver is shown in Figure 1. Although these divisions are useful for anatomic localization of tumors, it is often not possible to assign segmental location on resection specimens, and such information is best provided by the surgeon.

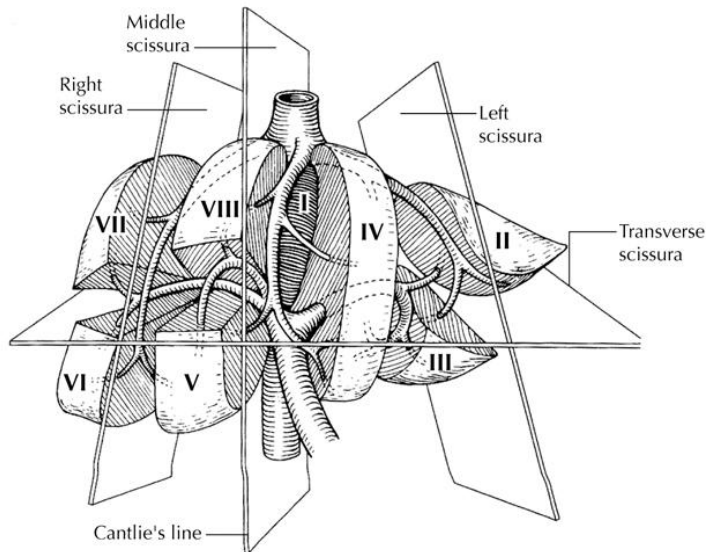


Figure 1. Segmental anatomy of the liver. From: Greene FL, Compton, CC, Fritz AG, et al, eds. *AJCC Cancer Staging Atlas*. New York: Springer; 2006. Copyright © American Joint Committee on Cancer. Used with permission.

Sections should be prepared from each major tumor nodule, with representative sampling of smaller nodules, if macroscopically different in appearance. Cirrhotic nodules appreciably larger than the surrounding background liver should also be sampled, because such nodules may harbor dysplastic changes.² For purposes of staging, satellite nodules, multifocal primary hepatocellular carcinomas, and intrahepatic metastases are not distinguished and are considered multiple tumors.

C. Histologic Type

The protocol recommends the following modified classification of the World Health Organization (WHO).³ In the United States, almost 70% of the primary malignant tumors of the liver are hepatocellular carcinomas.^{3,4}

WHO Classification of Carcinomas of the Liver (Modified)

Hepatocellular carcinoma

 Variant: Fibrolamellar hepatocellular carcinoma

Undifferentiated carcinoma

Multiple histologic architectural patterns, such as trabecular, solid, and pseudoglandular patterns, are often found in the same tumor in hepatocellular carcinoma,⁴ but only the fibrolamellar variant appears to have prognostic significance,⁵ although the relatively longer survival for this variant may relate to its occurrence in younger patients and in the noncirrhotic liver. Tumors that contain areas of both fibrolamellar carcinoma and typical hepatocellular carcinoma should not be classified as fibrolamellar carcinoma; this term should be reserved for those tumors showing only the fibrolamellar pattern.

D. Histologic Grade

Grading of Hepatocellular Carcinoma

The grading system of Edmondson and Steiner⁶ is recommended for hepatocellular carcinomas by this protocol and by the *AJCC Cancer Staging Manual*, 7th edition.¹ However, the use of other grading systems is not precluded.

Grade I	Reserved for hepatocellular carcinomas where the difference between the tumor cells and hyperplastic liver cells is so minor that a diagnosis of carcinoma rests upon the demonstration of more aggressive growths in other parts of the neoplasm. Because grade is assigned based upon the highest grade present, in effect grade I is rarely if ever used for overall tumor grade designation.
Grade II	Cells show marked resemblance to normal hepatic cells. Nuclei are larger and more hyperchromatic than in normal cells. Cytoplasm is abundant and acidophilic. Cell borders are sharp and clear cut. Acini are frequent and variable in size. Lumina are often filled with bile or protein precipitate.
Grade III	Nuclei are larger and more hyperchromatic than in grade II cells. The nuclei occupy a relatively greater proportion of the cell (high nuclear to cytoplasmic [N:C] ratio). Cytoplasm is granular and acidophilic, but less so than grade II tumors. Acini are less frequent and not as often filled with bile or protein precipitate. More single-cell growth in vascular channels is seen than in grade II.
Grade IV	Nuclei are intensely hyperchromatic. Nuclei occupy a high percentage of the cell. Cytoplasm is variable in amount, often scanty. Cytoplasm contains fewer granules. The growth pattern is medullary in character, trabeculae difficult to find, and cell masses seem to lie loosely without cohesion in vascular channels. Only rare acini are seen. Spindle cell areas have been seen in some tumors. Short plump cell forms, resembling “small cell” carcinoma of the lung, are seen in some grade IV tumors.

The pathologist should specify the grading system used. The higher the grade, the less the resemblance of the tumor to “normal” liver, and the more obvious its morphologic features are to malignant growth.

Histologic grade has been shown to have a relationship to tumor size, tumor presentation, and metastatic rate.⁷ Low histologic grade has been shown to be predictive of disease-free survival, but not of overall actuarial survival.

E. Margins

The evaluation of margins for total or partial hepatectomy specimens depends on the method and extent of resection. It is recommended that the surgeon be consulted to determine the critical foci within the margins that require microscopic evaluation. The transection margin of a partial hepatectomy may be large, rendering it impractical for complete examination. In this setting, grossly positive margins should be microscopically confirmed and documented. If the margins are grossly free of tumor, judicious sampling of the cut surface in the region closest to the nearest identified tumor nodule is indicated. In selected cases, adequate random sampling of the cut surface may be sufficient. If the neoplasm is found near the surgical margin, the distance from the margin should be reported. For multiple tumors, the distance from the nearest tumor should be reported.

F. Venous and Small Vessel Invasion

Vascular invasion includes gross as well as microscopic invasion of vessels. Macroscopic venous invasion is generally accompanied by microscopic invasion,⁸ but it is less commonly found than microscopic invasion alone (15% versus 43%). Both are associated with lower survival post-resection. Larger tumors (greater than 5 cm) or multiple tumors are more likely to exhibit vascular invasion than single small lesions.⁹

G. TNM and Anatomic Stage/Prognostic Groupings

The TNM staging system of the American Joint Committee on Cancer (AJCC) and the International Union Against Cancer (UICC) applies to hepatocellular carcinomas.¹ It does not apply to hepatic sarcomas or to metastatic tumors of the liver. The T classification depends on the number of tumor nodules, the size of the largest nodule, and the presence or absence of blood vessel invasion. The TNM classification does not discriminate between multiple independent primary tumors or intrahepatic metastasis from a single primary hepatic carcinoma. Vascular invasion includes either the gross or the histologic involvement of vessels. Portal vein invasion is an important adverse prognostic factor and should be reported.

According to AJCC/UICC convention, the designation “T” refers to a primary tumor that has not been previously treated. The symbol “p” refers to the pathologic classification of the TNM, as opposed to the clinical classification, and is based on gross and microscopic examination. pT entails a resection of the primary tumor or biopsy adequate to evaluate the highest pT category, pN entails removal of nodes adequate to validate lymph node metastasis, and pM implies microscopic examination of distant lesions. Clinical classification (cTNM) is usually carried out by the referring physician before treatment during initial evaluation of the patient or when pathologic classification is not possible.

Pathologic staging is usually performed after surgical resection of the primary tumor. Pathologic staging depends on pathologic documentation of the anatomic extent of disease, whether or not the primary tumor has been completely removed. If a biopsied tumor is not resected for any reason (eg, when technically infeasible) and if the highest T and N categories or the M1 category of the tumor can be confirmed microscopically, the criteria for pathologic classification and staging have been satisfied without total removal of the primary cancer.

TNM Descriptors

For identification of special cases of TNM or pTNM classifications, the “m” suffix and “y,” “r,” and “a” prefixes are used. Although they do not affect the stage grouping, they indicate cases needing separate analysis.

The “m” suffix indicates the presence of multiple primary tumors in a single site and is recorded in parentheses: pT(m)NM.

The “y” prefix indicates those cases in which classification is performed during or after initial multimodality therapy (ie, neoadjuvant chemotherapy, radiation therapy, or both chemotherapy and radiation therapy). The cTNM or pTNM category is identified by a “y” prefix. The ycTNM or ypTNM categorizes the extent of tumor actually present at the time of that examination. The “y” categorization is not an estimate of tumor before multimodality therapy (ie, before initiation of neoadjuvant therapy).

The “r” prefix indicates a recurrent tumor when staged after a documented disease-free interval and is identified by the “r” prefix: rTNM.

The “a” prefix designates the stage determined at autopsy: aTNM.

Primary Tumor (T) (Figures 2 through 5)

- TX Primary tumor cannot be assessed
- T0 No evidence of primary tumor
- T1 Solitary tumor without vascular invasion
- T2 Solitary tumor with vascular invasion; or multiple tumors, none more than 5 cm in greatest dimension
- T3 Multiple tumors more than 5 cm in greatest dimension or tumor involving a major branch of the portal or hepatic veins(s)
 - T3a Multiple tumors more than 5 cm
 - T3b Tumor(s) any size involving a major branch of the portal or hepatic vein(s)
- T4 Tumor(s) with direct invasion of adjacent organs other than the gallbladder or with perforation of visceral peritoneum

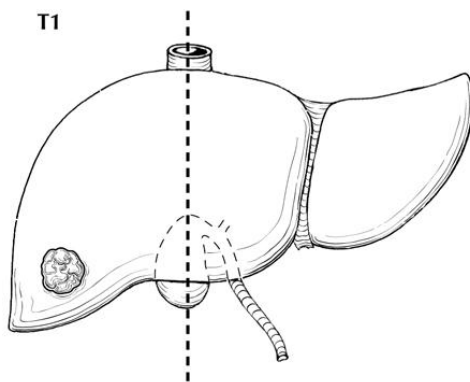


Figure 2. T1 is defined as a solitary tumor without vascular invasion. From: Greene FL, Compton, CC, Fritz AG, et al, eds. *AJCC Cancer Staging Atlas*. New York: Springer; 2006. Copyright © American Joint Committee on Cancer. Used with permission.

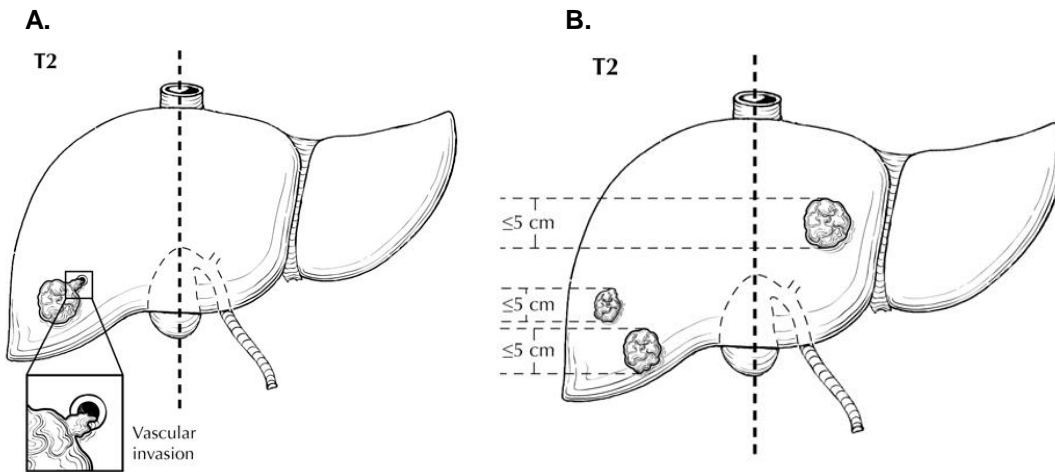


Figure 3. A. Solitary tumors with vascular invasion, regardless of size, are classified as T2. B. Multiple tumors, none measuring 5 cm in greatest dimension, are classified as T2. From: Greene FL, Compton, CC, Fritz AG, et al, eds. *AJCC Cancer Staging Atlas*. New York: Springer; 2006. Copyright © American Joint Committee on Cancer. Used with permission.

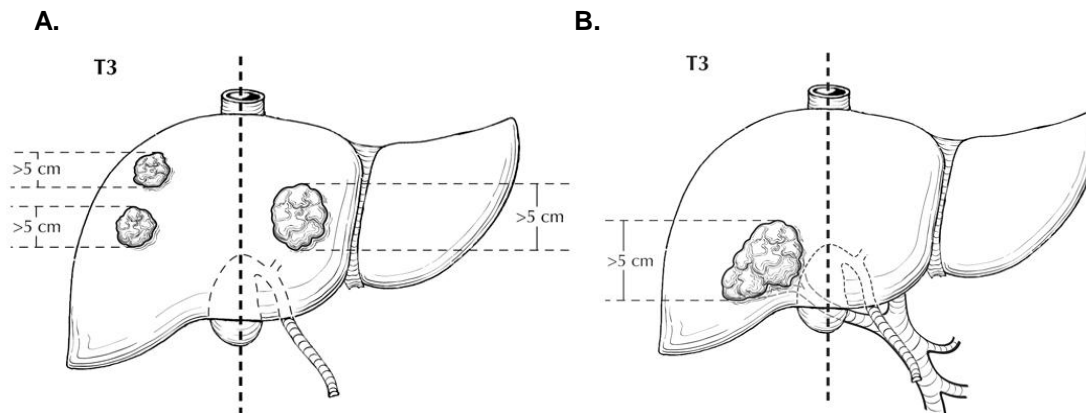


Figure 4. A. Multiple tumors, any more than 5 cm, are classified as T3a. B. Tumor involving a major branch of the portal or hepatic vein(s) is classified as T3b. From: Greene FL, Compton, CC, Fritz AG, et al, eds. *AJCC Cancer Staging Atlas*. New York: Springer; 2006. Copyright © American Joint Committee on Cancer. Used with permission.

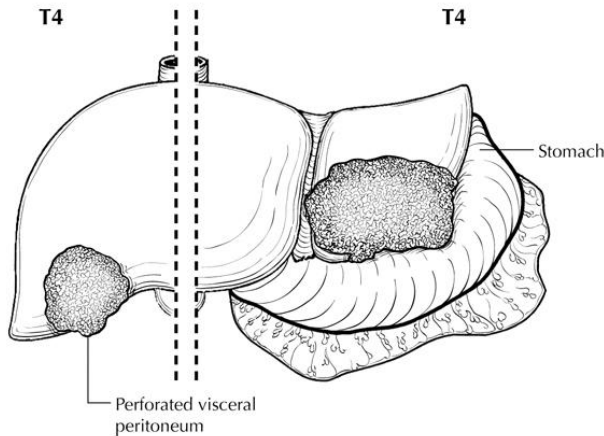


Figure 5. Tumor with direct invasion of adjacent organs other than gallbladder or with perforation of the visceral peritoneum is classified as T4. From: Greene FL, Compton, CC, Fritz AG, et al, eds. *AJCC Cancer Staging Atlas*. New York: Springer; 2006. Copyright © American Joint Committee on Cancer. Used with permission.

Regional Lymph Nodes (N)

- NX Regional lymph nodes cannot be assessed
 N0 No regional lymph node metastasis
 N1 Regional lymph node metastasis

Distant Metastasis (M)

- M0 No distant metastasis
 M1 Distant metastasis

Stage Groupings

Stage I	T1	N0	M0
Stage II	T2	N0	M0
Stage IIIA	T3a	N0	M0
IIIB	T3b	N0	M0
IIIC	T4	N0	M0
Stage IVA	any T	N1	M0
Stage IVB	any T	any N	M1

Lymph Nodes

Histologic examination of a regional lymphadenectomy specimen usually involves examination of 3 or more lymph nodes. The regional lymph nodes of the hepatic region include the hilar, hepatoduodenal ligament, inferior phrenic, and caval lymph nodes. Nodal involvement of lymph nodes distal to the hilar, hepatoduodenal ligament, and caval lymph nodes are considered as indicative of distant metastasis (pM1).

H. Additional Pathologic Findings

Fibrosis

Cirrhosis or severe fibrosis (Ishak score 5 or 6) should be specifically reported because it has an adverse effect on outcome.¹⁰ The scoring system described by Ishak¹¹ is recommended by the *AJCC Cancer Staging Manual*, 7th edition,¹ and by this protocol.

Degree of Fibrosis	Score
None	0
Fibrous expansion of some portal areas, with or without short fibrous septa	1
Fibrous expansion of most portal areas	2
Fibrous expansion of most portal areas with occasional portal-portal bridging	3
Fibrous expansion of portal areas with marked bridging as well as portal-to-central bridging	4
Marked bridging with occasional nodules (incomplete cirrhosis)	5
Cirrhosis	6

Source: Ishak et al.¹¹

Dysplastic Nodules

Reporting of dysplastic changes in cirrhotic nodules is optional in specimens with hepatocellular carcinoma, but it may be helpful in assessing risk for second primary tumors in patients undergoing partial hepatectomy. Dysplastic nodules are generally considered important precursors to hepatocellular carcinoma. The criteria outlined by the International Working Party are recommended,² although difficulties in assessment of these lesions and variation in interobserver agreement are recognized.

In brief, dysplastic nodules are nodular lesions displaying some degree of cytologic or architectural atypia but lacking definitive histologic features of malignancy. Dysplastic nodules are further subdivided into low and high grades, depending on the degree of histologic abnormality.

Feature	Low-Grade Dysplastic Nodule	High-Grade Dysplastic Nodule
Nuclear atypia	Minimal	Hyperchromasia and pleomorphism
Small cell change [#]	Rare	May be present
Clone-like growth pattern (uniform population of hepatocytes with map-like growth pattern)	Present	Present; may have nodule-within-nodule growth pattern suggestive of subclone evolution
Liver cell plates	1 to 2 cell layers thick	Focal areas more than 2 cells thick
Unpaired arteries	Rare	Common

[#] Characterized by smaller cell size, a greater nuclear to cytoplasmic ratio, cytoplasmic basophilia, and denser cellularity in comparison with the surrounding extranodular hepatocytes.

Specific types of underlying disease, such as viral hepatitis or hemochromatosis, should be separately evaluated and graded, if appropriate.

I. Clinical History

Hepatocellular carcinoma (HCC) is highly linked to chronic liver disease, in particular chronic hepatitis B (HBV) and C (HCV) infection and alcoholic liver disease. Overall, 50%

to 55% of cases of HCC worldwide are attributed to HBV and 25% to 30% to HCV,¹² but virtually any condition associated with chronic hepatic injury and especially with cirrhosis may predispose to HCC. The annual risk of HCC developing in a cirrhotic liver is estimated at 1% to 6%, with the risk generally highest in the context of chronic viral infection and hereditary hemochromatosis. Nonalcoholic fatty liver disease is increasingly recognized as a risk factor for HCC.¹³

References

1. Edge SB, Byrd DR, Carducci MA, Compton CC, eds. *AJCC Cancer Staging Manual*. 7th ed. New York, NY: Springer; 2009.
2. International Working Party. Terminology of nodular hepatocellular lesions. *Hepatology*. 1995;22:983-993.
3. Hirohashi S, Ishak KG, Kojiro M, et al. Hepatocellular carcinoma. In: Hamilton SR, Aaltonen LA, eds. *World Health Organization Classification of Tumours: Pathology and Genetics of Tumours of the Digestive System*. Lyon, France: IARC Press; 2000.
4. Ishak KG, Goodman ZD, Stocker JT. *Tumors of the Liver and Intrahepatic Bile Ducts*. Vol 3rd series, fascicle 31. Washington, DC: Armed Forces Institute of Pathology; 2001.
5. Stipa F, Yoon SS, Liao KH, et al. Outcome of patients with fibrolamellar hepatocellular carcinoma. *Cancer*. Mar 15 2006;106(6):1331-1338.
6. Edmonson HA, Steiner PE. Primary carcinoma of the liver. *Cancer*. 1954;7:462-503.
7. Lauwers GY, Terris B, Balis UJ, et al. Prognostic histologic indicators of curatively resected hepatocellular carcinomas: a multi-institutional analysis of 425 patients with definition of a histologic prognostic index. *Am J Surg Pathol*. 2002;26:23-34.
8. Tsai T-J, Chau G-Y, Lui W-Y, et al. Clinical significance of microscopic tumor venous invasion in patients with resectable hepatocellular carcinoma. *Surgery*. 2000;127:603-608.
9. Pawlik TM, Delman KA, Vauthey J-N, et al. Tumor size predicts vascular invasion and histologic grade: implications for expanding the criteria for hepatic transplantation. *Liver Transpl*. 2005;11(9):1086-1092.
10. Bilmoria MM, Lauwers GY, Doherty DA, et al. Underlying liver disease, not tumor factors, predicts long-term survival after resection of hepatocellular carcinoma. *Arch Surg*. 2001;136:528-535.
11. Ishak K, Baptista A, Bianchi L, et al. Histologic grading and staging of chronic hepatitis. *J Hepatol*. 1995;22:696-699.
12. El-Serag HB, Rudolph KL. Hepatocellular carcinoma: epidemiology and molecular carcinogenesis. *Gastroenterology*. Jun 2007;132(7):2557-2576.
13. Caldwell SH, Crespo DM, Kang HS, Al-Osaimi AMS. Obesity and hepatocellular carcinoma. *Gastroenterology*. Nov 2004;127(5 Suppl 1):S97-103.