

Protocol for the Examination of Specimens from Patients with Carcinoma of the Ureter and Renal Pelvis

Protocol applies to invasive and in-situ carcinomas and/or associated epithelial lesions of the ureter and renal pelvis.

Based on AJCC/UICC TNM, 7th edition
Protocol web posting date: October 2009

Procedures

- Biopsy
- Nephroureterectomy or Ureterectomy

Authors

Peter A. Humphrey, MD, PhD*
Department of Pathology and Immunology, Washington University School of Medicine
and Barnes-Jewish Hospital, St. Louis, Missouri

Mahul B. Amin, MD†
Department of Pathology, Cedars-Sinai Hospital, Los Angeles, California

John R. Srigley, MD
Department of Laboratory Medicine, Credit Valley Hospital, Mississauga,
Ontario, Canada

Anthony Chang, MD
Department of Pathology, The University of Chicago Medical Center, Chicago, Illinois

Arthur H. Cohen, MD
Department of Pathology, Cedars-Sinai Hospital, Los Angeles, California

Brett Delahunt, MD
Department of Pathology and Molecular Medicine, Wellington School of Medicine and
Health, New Zealand

Jonathan I. Epstein, MD
Department of Pathology, The Johns Hopkins Hospital, Baltimore, Maryland

David J. Grignon, MD
Department of Pathology, Indiana University School of Medicine, Indianapolis, Indiana

Rodolfo Montironi, MD
Institute of Pathological Anatomy and Histopathology, University of Ancona School of
Medicine, Ancona, Italy

Andrew A. Renshaw, MD
Department of Pathology, Baptist Hospital of Miami, Miami, Florida

Victor E. Reuter, MD
Department of Pathology, Memorial Sloan-Kettering Cancer Center, New York
For the Members of the Cancer Committee, College of American Pathologists

* denotes primary author. † denotes senior author.

Previous lead contributor: Donald Earl Henson, MD

© 2009 College of American Pathologists (CAP). All rights reserved.

The College does not permit reproduction of any substantial portion of these protocols without its written authorization. The College hereby authorizes use of these protocols by physicians and other health care providers in reporting on surgical specimens, in teaching, and in carrying out medical research for nonprofit purposes. This authorization does not extend to reproduction or other use of any substantial portion of these protocols for commercial purposes without the written consent of the College.

The CAP also authorizes physicians and other health care practitioners to make modified versions of the Protocols solely for their individual use in reporting on surgical specimens for individual patients, teaching, and carrying out medical research for non-profit purposes.

The CAP further authorizes the following uses by physicians and other health care practitioners, in reporting on surgical specimens for individual patients, in teaching, and in carrying out medical research for non-profit purposes: (1) **Dictation** from the original or modified protocols for the purposes of creating a text-based patient record on paper, or in a word processing document; (2) **Copying** from the original or modified protocols into a text-based patient record on paper, or in a word processing document; (3) The use of a **computerized system** for items (1) and (2), provided that the Protocol data is stored intact as a single text-based document, and is not stored as multiple discrete data fields.

Other than uses (1), (2), and (3) above, the CAP does not authorize any use of the Protocols in electronic medical records systems, pathology informatics systems, cancer registry computer systems, computerized databases, mappings between coding works, or any computerized system without a written license from CAP. Applications for such a license should be addressed to the SNOMED Terminology Solutions division of the CAP.

Any public dissemination of the original or modified Protocols is prohibited without a written license from the CAP.

The College of American Pathologists offers these protocols to assist pathologists in providing clinically useful and relevant information when reporting results of surgical specimen examinations of surgical specimens. The College regards the reporting elements in the “Surgical Pathology Cancer Case Summary (Checklist)” portion of the protocols as essential elements of the pathology report. However, the manner in which these elements are reported is at the discretion of each specific pathologist, taking into account clinician preferences, institutional policies, and individual practice.

The College developed these protocols as an educational tool to assist pathologists in the useful reporting of relevant information. It did not issue the protocols for use in litigation, reimbursement, or other contexts. Nevertheless, the College recognizes that the protocols might be used by hospitals, attorneys, payers, and others. Indeed, effective January 1, 2004, the Commission on Cancer of the American College of Surgeons mandated the use of the checklist elements of the protocols as part of its Cancer Program Standards for Approved Cancer Programs. Therefore, it becomes even more important for pathologists to familiarize themselves with these documents. At the same time, the College cautions that use of the protocols other than for their intended educational purpose may involve additional considerations that are beyond the scope of this document.

The inclusion of a product name or service in a CAP publication should not be construed as an endorsement of such product or service, nor is failure to include the name of a product or service to be construed as disapproval.

CAP Ureter, Renal Pelvis Protocol Revision History

Version Code

The definition of the version code can be found at www.cap.org/cancerprotocols.

Version: UreterRenalPelvis 3.0.0.0

Summary of Changes

No changes have been made since the October 2009 release.

Surgical Pathology Cancer Case Summary (Checklist)

Protocol web posting date: October 2009

URETER, RENAL PELVIS: Biopsy**Note: Use of checklist for biopsy specimens is optional.****Select a single response unless otherwise indicated.*****Specimen (Note A)**

- * Renal pelvis
- * Ureter
- * Other (specify): _____
- * Not specified

***Specimen Laterality**

- * Left
- * Right
- * Not specified

***Histologic Type (Note B)**

- * Urothelial (transitional cell) carcinoma
- * Urothelial (transitional cell) carcinoma with squamous differentiation
- * Urothelial (transitional cell) carcinoma with glandular differentiation
- * Urothelial (transitional cell) carcinoma with variant histology
(specify): _____
- * Squamous cell carcinoma, typical
- * Squamous cell carcinoma, variant histology (specify): _____
- * Adenocarcinoma, typical
- * Adenocarcinoma, variant histology (specify): _____
- * Small cell carcinoma
- * Undifferentiated carcinoma (specify): _____
- * Mixed cell type (specify): _____
- * Other (specify): _____
- * Carcinoma, type cannot be determined

***Associated Epithelial Lesions (select all that apply) (Note C)**

- * None identified
- * Urothelial (transitional cell) papilloma (World Health Organization [WHO] / International Society of Urologic Pathology [ISUP], 1998; WHO 2004)
- * Urothelial (transitional cell) papilloma, inverted type
- * Papillary urothelial (transitional cell) neoplasm, low malignant potential (WHO/ISUP 1998; WHO 2004)
- * Cannot be determined

* Data elements with asterisks are not required. However, these elements may be clinically important but are not yet validated or regularly used in patient management.

Histologic Grade (Note C) Not applicable* Cannot be determined***Urothelial Carcinoma (WHO/ISUP, 1998; WHO 2004)*** Low-grade* High-grade* Other (specify): _____***Adenocarcinoma and Squamous Cell Carcinoma*** GX: Cannot be assessed* G1: Well differentiated* G2: Moderately differentiated* G3: Poorly differentiated* Other (specify): _____***Tumor Configuration (select all that apply)*** Papillary* Solid/nodule* Flat* Ulcerated* Indeterminate* Other (specify): _____***Adequacy of Material for Determining T Category (Note D)*** Muscularis propria not identified* Muscularis propria present* Indeterminate***Pathologic Staging (pTNM) (Note E)*****TNM Descriptors (select all that apply)*** None* m (multiple primary tumors)* r (recurrent)* y (post-treatment)***Primary Tumor (pT)*** pTX: Cannot be assessed* pT0: No evidence of primary tumor* pTa: Noninvasive papillary carcinoma* pTis: Flat carcinoma in situ* pT1: Tumor invades subepithelial connective tissue (lamina propria)* pT2: Tumor invades muscularis propria

* Data elements with asterisks are not required. However, these elements may be clinically important but are not yet validated or regularly used in patient management.

***Additional Pathologic Findings (select all that apply)**

- * Urothelial carcinoma in situ
- * Urothelial dysplasia (low-grade intraurothelial neoplasia)
- * Inflammation/regenerative changes
- * Therapy-related changes
- * Cautery artifact
- * Ureteritis or pyelitis cystica and/or glandularis
- * Keratinizing squamous metaplasia
- * Intestinal metaplasia
- * Other (specify): _____

***Comment(s)**

* Data elements with asterisks are not required. However, these elements may be clinically important but are not yet validated or regularly used in patient management.

Surgical Pathology Cancer Case Summary (Checklist)

Protocol web posting date: October 2009

RENAL PELVIS: Resection/Nephroureterectomy, Partial or Complete

Select a single response unless otherwise indicated.

Procedure (Note F)

- Nephroureterectomy, partial
 Nephroureterectomy, complete
 Other (specify): _____
 Not specified

Specimen Laterality

- Right
 Left
 Not specified

Tumor Size

- Greatest dimension: ____ cm
 *Additional dimensions: ____ x ____ cm
 Cannot be determined (see Comment)

Histologic Type (Note B)

- Urothelial (transitional cell) carcinoma
 Urothelial (transitional cell) carcinoma with squamous differentiation
 Urothelial (transitional cell) carcinoma with glandular differentiation
 Urothelial (transitional cell) carcinoma with variant histology
 (specify): _____
 Squamous cell carcinoma, typical
 Squamous cell carcinoma, variant histology
 (specify): _____
 Adenocarcinoma, typical
 Adenocarcinoma, variant histology (specify): _____
 Small cell carcinoma
 Undifferentiated carcinoma (specify): _____
 Mixed cell type (specify): _____
 Other (specify): _____
 Carcinoma, type cannot be determined

Associated Epithelial Lesions (select all that apply) (Note C)

- None identified
 Urothelial (transitional cell) papilloma (World Health Organization [WHO] / International Society of Urologic Pathology [ISUP], 1998; WHO 2004)
 Urothelial (transitional cell) papilloma, inverted type
 Papillary urothelial (transitional cell) neoplasm, low malignant potential (WHO/ISUP 1998; WHO 2004)
 Cannot be determined

* Data elements with asterisks are not required. However, these elements may be clinically important but are not yet validated or regularly used in patient management.

Histologic Grade (Note C)

- Not applicable
 Cannot be determined

Urothelial Carcinoma (WHO/ISUP, 1998; WHO 2004)

- Low-grade
 High-grade
 Other (specify): _____

Adenocarcinoma and Squamous Cell Carcinoma

- GX: Cannot be assessed
 G1: Well differentiated
 G2: Moderately differentiated
 G3: Poorly differentiated
 Other (specify): _____

***Tumor Configuration (select all that apply)**

- * Papillary
 * Solid/nodule
 * Flat
 * Ulcerated
 * Indeterminate
 * Other (specify): _____

Margins (select all that apply) (Note G)

- Cannot be assessed
 Margins uninvolved by invasive carcinoma
 *Distance of invasive carcinoma from closest margin: ___ mm
 *Specify margin: _____
 Margin(s) involved by invasive carcinoma
 Specify margin(s): _____
 Margin(s) uninvolved by carcinoma in situ
 Margin(s) involved by carcinoma in situ
 Specify margin(s): _____
 Other(s) (specify): _____

***Lymph-Vascular Invasion (Note H)**

- * Not identified
 * Present
 * Indeterminate

Pathologic Staging (pTNM) (Note E)**TNM Descriptors (required only if applicable) (select all that apply)**

- m (multiple)
 r (recurrent)
 y (post-treatment)

* Data elements with asterisks are not required. However, these elements may be clinically important but are not yet validated or regularly used in patient management.

Primary Tumor (pT)

- pTX: Cannot be assessed
 pT0: No evidence of primary tumor
 pTa: Papillary noninvasive carcinoma
 pTis: Flat carcinoma in situ
 pT1: Tumor invades subepithelial connective tissue (lamina propria)
 pT2: Tumor invades muscularis propria
 pT3: Tumor invades beyond muscularis into peripelvic fat or the renal parenchyma
 pT4: Tumor invades adjacent organs, or through the kidney into the perinephric fat

Regional Lymph Nodes (pN)

- pNX: Cannot be assessed
 pN0: No regional lymph node metastasis
 pN1: Metastasis in a single regional lymph node, 2 cm or less in greatest dimension
 pN2: Metastasis in a single regional lymph node, more than 2 cm but not more than 5 cm in greatest dimension, or multiple lymph nodes, none more than 5 cm in greatest dimension
 pN3: Metastasis in a regional lymph node more than 5 cm in greatest dimension
 Specify: Number examined: ____
 Number involved (any size): ____

Distant Metastasis (pM)

- Not applicable
 pM1: Distant metastasis
 *Specify site(s), if known: _____

***Additional Pathologic Findings (select all that apply)**

- * Urothelial carcinoma in situ
 * Urothelial dysplasia (low-grade intraurothelial neoplasia)
 * Inflammation/regenerative changes
 * Therapy-related changes
 * Pyelitis cystica and/or glandularis
 * Keratinizing squamous metaplasia
 * Intestinal metaplasia
 * Lithiasis
 * Other (specify): _____

***Comment(s)**

* Data elements with asterisks are not required. However, these elements may be clinically important but are not yet validated or regularly used in patient management.

Surgical Pathology Cancer Case Summary (Checklist)

Protocol web posting date: October 2009

URETER: Resection

Select a single response unless otherwise indicated.

Procedure

- Ureterectomy
 Nephroureterectomy
 Other (specify): _____
 Not specified

Specimen Laterality

- Right
 Left
 Not specified

Tumor Size

- Greatest dimension: ____
 *Additional dimensions: ____ x ____
 Cannot be determined (see Comment)

Histologic Type (Note B)

- Urothelial (transitional cell) carcinoma
 Urothelial (transitional cell) carcinoma with squamous differentiation
 Urothelial (transitional cell) carcinoma with glandular differentiation
 Urothelial (transitional cell) carcinoma with variant histology
 (specify): _____
 Squamous cell carcinoma, typical
 Squamous cell carcinoma, variant histology
 (specify): _____
 Adenocarcinoma, typical
 Adenocarcinoma, variant histology (specify): _____
 Small cell carcinoma
 Undifferentiated carcinoma (specify): _____
 Mixed cell type (specify): _____
 Other (specify): _____
 Carcinoma, type cannot be determined

Associated Epithelial Lesions (select all that apply) (Note C)

- None identified
 Urothelial (transitional cell) papilloma (World Health Organization [WHO] / International Society of Urologic Pathology [ISUP], 1998; WHO 2004)
 Urothelial (transitional cell) papilloma, inverted type
 Papillary urothelial (transitional cell) neoplasm, low malignant potential (WHO/ISUP 1998; WHO 2004)
 Cannot be determined

* Data elements with asterisks are not required. However, these elements may be clinically important but are not yet validated or regularly used in patient management.

Histologic Grade (Note C)

- Not applicable
 Cannot be determined

Urothelial Carcinoma (WHO/ISUP, 1998; WHO 2004)

- Low-grade
 High-grade
 Other (specify): _____

Adenocarcinoma and Squamous Cell Carcinoma

- GX: Cannot be assessed
 G1: Well differentiated
 G2: Moderately differentiated
 G3: Poorly differentiated
 Other (specify): _____

***Tumor Configuration (select all that apply)**

- * Papillary
 * Solid/nodule
 * Ulcerated
 * Flat
 * Indeterminate
 * Other (specify): _____

Margins (select all that apply) (Note G)

- Cannot be assessed
 Margins uninvolved by invasive carcinoma
 *Distance of invasive carcinoma from closest margin: ____ mm
 *Specify margin(s): _____
 Margin(s) involved by invasive carcinoma
 Specify margin(s): _____
 Margins(s) involved by carcinoma in situ
 Margin(s) uninvolved by carcinoma in situ
 Other(s) (specify): _____

***Lymph-Vascular Invasion (Note H)**

- * Not identified
 * Present
 * Indeterminate

Pathologic Staging (pTNM) (Note E)**TNM Descriptors (required only if applicable) (select all that apply)**

- m (multiple)
 r (recurrent)
 y (post-treatment)

* Data elements with asterisks are not required. However, these elements may be clinically important but are not yet validated or regularly used in patient management.

Primary Tumor (pT)

- pTX: Cannot be assessed
 pT0: No evidence of primary tumor
 pTa: Papillary noninvasive carcinoma
 pTis: Carcinoma in situ
 pT1: Tumor invades subepithelial connective tissue (lamina propria)
 pT2: Tumor invades the muscularis propria
 pT3: Tumor invades beyond muscularis propria into periureteric fat
 pT4: Tumor invades adjacent organs

Regional Lymph Nodes (pN)

- pNX: Cannot be assessed
 pN0: No regional lymph node metastasis
 pN1: Metastasis in a single regional lymph node, 2 cm or less in greatest dimension
 pN2: Metastasis in a single regional lymph node, more than 2 cm but not more than 5 cm in greatest dimension, or multiple lymph nodes, none more than 5 cm in greatest dimension
 pN3: Metastasis in a regional lymph node more than 5 cm in greatest dimension
 Specify: Number examined: ____
 Number involved (any size): ____

Distant Metastasis (pM)

- Not applicable
 pM1: Distant metastasis
 *Specify site(s), if known: _____

***Additional Pathologic Findings (select all that apply)**

- * Urothelial carcinoma in situ
 * Urothelial dysplasia (low-grade intraurothelial neoplasia)
 * Inflammation/regenerative changes
 * Therapy-related changes
 * Ureteritis cystica and/or glandularis
 * Keratinizing squamous metaplasia
 * Intestinal metaplasia
 * Other (specify): _____

Pathologic Findings in Non-Neoplastic Kidney (select all that apply) (Note I)

- Insufficient tissue (partial nephrectomy specimen with <5 mm of adjacent non-neoplastic kidney)
 Significant pathologic alterations
 None identified
 Glomerular disease (type): _____
 Tubulointerstitial disease (type): _____
 Vascular disease (type): _____
 Inflammation (type): _____
 Other (specify): _____

***Comment(s)**

* Data elements with asterisks are not required. However, these elements may be clinically important but are not yet validated or regularly used in patient management.

Explanatory Notes

A. History

A relevant history is important for interpretation of all upper urinary tract (renal pelvis and ureter) specimens. A history of renal stones, recent urinary tract procedures, infections, or obstruction can influence the interpretation of random biopsies obtained from patients with hematuria. Any neoplasms previously diagnosed should be specified, including the histologic type, primary site, and histologic grade. Primary tumors may be associated with hereditary non-polyposis colon cancer (HNPCC) syndrome (Lynch syndrome II). Renal pelvic tumors are more often seen in analgesic abusers, who often have analgesic nephropathy, including papillary necrosis. If prior therapy has been given, it should be described (systemic or intravesical chemotherapy, immunotherapy, radiation, etc). The method of collection and date also should be specified in urine cytology specimens. Cytologic specimens from the ureter or renal pelvis may be over-interpreted if their site of sampling is not stated.

B. Histologic Type

Like the urinary bladder, the vast majority (more than 95%) of carcinomas of the renal pelvis and ureter are urothelial in origin.¹⁻⁶ A working histologic classification encompassing the wide histologic diversity and histologic range within the different types of carcinomas of the urothelial tract is tabulated in this note. Benign tumors are included in this classification because, within the same patient, a spectrum of differentiation from benign to malignant tumors may be seen, either at the same time or over the clinical course of the disease. The full spectrum of invasive urothelial carcinoma and its variants as found in the urinary bladder may also be found in the upper tract. Of note, unusual histomorphological variants seem to be more common in the upper tract,⁶ including carcinomas with micropapillary, lymphoepithelioma-like, sarcomatoid, squamous, clear cell, glandular, rhabdoid, signet-ring, and plasmacytoid features or areas. The distinction between a urothelial carcinoma with aberrant squamous or glandular differentiation and a primary squamous cell carcinoma or adenocarcinoma is rather arbitrary. Most authorities require a pure histology of squamous cell carcinoma or adenocarcinoma to designate a tumor as such, all others with recognizable papillary, invasive, or flat carcinoma in situ (CIS) urothelial component being considered as urothelial carcinoma with aberrant differentiation.

Classification of Neoplasms of the Ureter and Renal Pelvis, Including Urothelial (Transitional Cell) Carcinoma and Its Variants[#]

Urothelial (Transitional Cell) Neoplasia (World Health Organization [WHO] / International Society of Urologic Pathology [ISUP], 1998; WHO 2004)

Benign

Urothelial papilloma

Inverted papilloma

Papillary urothelial neoplasm of low malignant potential

Malignant

Papillary^{##}

Typical, noninvasive

Typical, with invasion

Variant

With squamous or glandular differentiation

- Micropapillary
 - Nonpapillary
 - Carcinoma in situ
 - Invasive carcinoma
 - Variants containing or exhibiting
 - Deceptively benign features
 - Nested pattern (resembling von Brunn's nests)
 - Small tubular pattern
 - Microcystic pattern
 - Inverted pattern
 - Squamous differentiation
 - Glandular differentiation
 - Micropapillary histology
 - Sarcomatoid foci ("sarcomatoid carcinoma")
 - Urothelial carcinoma with unusual cytoplasmic features
 - Clear cell
 - Plasmacytoid
 - Urothelial carcinoma with syncytiotrophoblasts
 - Unusual stromal reactions
 - Pseudosarcomatous stroma
 - Stromal osseous or cartilaginous metaplasia
 - Osteoclast-type giant cells
 - With prominent lymphoid infiltrate
- Squamous Cell Carcinoma
 - Typical
 - Variants
 - Verrucous carcinoma
 - Basaloid squamous cell carcinoma
 - Sarcomatoid carcinoma
- Adenocarcinoma
 - Histologic variants
 - Typical intestinal type
 - Mucinous (including colloid)
 - Signet-ring cell
 - Clear cell
 - Hepatoid
 - Mixture of above patterns – adenocarcinoma not otherwise specified (NOS)
- Tumors of Mixed Cell Types
- Undifferentiated Carcinoma^{###}
 - Small cell carcinoma
 - Large cell neuroendocrine carcinoma
 - Lymphoepithelioma-like carcinoma
 - Giant cell carcinoma
 - Not otherwise specified
- Metastatic Carcinoma

Modified from Amin et al.⁷

Papillary tumors may be invasive or noninvasive.

Refers to tumors that are undifferentiated by light microscopy.

C. Histologic Grade

The grading system is identical to that for urinary bladder neoplasms. Flat intraepithelial lesions and papillary and invasive lesions are graded separately. There has been significant controversy in the classification of these lesions. Due to variable classification systems and the need for a universally acceptable system, the World Health Organization/International Society of Urological Pathology (WHO/ISUP) consensus classification was proposed.⁸ This system is utilized in the WHO 2004 “blue book”¹ and the 2004 AFIP Fascicle.² Urothelial carcinomas of the renal pelvis tend to more often be high-grade^{3,9} compared to urinary bladder carcinomas.

WHO/ISUP (1998) and WHO 2004 Consensus Classification for Urothelial (Transitional Cell) Lesions

Normal

Normal[#]

Hyperplasia

Flat hyperplasia

Papillary hyperplasia

Flat Lesions with Atypia

Reactive (inflammatory) atypia

Atypia of unknown significance

Dysplasia (low-grade intraurothelial neoplasia)

Carcinoma in situ (high-grade intraurothelial neoplasia)^{##}

Papillary Neoplasms

Papilloma

Inverted papilloma

Papillary neoplasm of low malignant potential

Papillary carcinoma, low-grade

Papillary carcinoma, high-grade^{###}

Invasive Neoplasms

Lamina propria invasion

Muscularis propria invasion

[#] May include cases formerly diagnosed as “mild dysplasia.”

^{##} Includes cases with “severe dysplasia.”

^{###} Option exists to add comment as to the presence of marked anaplasia.

Squamous carcinomas and adenocarcinomas may be graded as well differentiated, moderately differentiated, and poorly differentiated.

D. Extent of Invasion

Depth of invasion and pathologic stage are the most important prognostic indicators for patients with neoplasms of the upper urinary tract.^{10,11} A critical role of the surgical pathologist is to diagnose the depth and extent of invasion into the subepithelial connective tissue/lamina propria (pT1), muscularis propria (pT2), or beyond (pT3 or pT4). The patterns of invasion are similar to the urinary bladder, except that for renal pelvis carcinoma, the type of tumor involvement of the kidney, when present, impacts

stage. Also, it is important to note that the lamina propria is absent beneath the urothelium lining the renal papillae in the pelvis and is thin along the minor calyces.¹² As in the urinary bladder, in papillary tumors, invasion occurs most often at the base of the tumor and very infrequently in the stalk. Tumor infiltrating the lamina propria is pT1 and, like the urinary bladder, there is no accepted approach for assessing depth of lamina propria invasion. However, pathologists are encouraged to provide some assessment as to the extent of lamina propria invasion (ie, focal versus extensive, or depth in millimeters, or by level – above, at, or below muscularis mucosae). Designation of a tumor as merely muscle invasive is inappropriate, but the type of muscle invasion, ie, muscularis mucosae (pT1 tumors) versus muscularis propria (pT2 tumors) invasion, needs to be clearly stated. Descriptive terminology, such as “urothelial carcinoma with muscle invasion, indeterminate for type of muscle invasion,” may be used when it is not possible to be certain whether the type of muscle invaded by the tumor is hypertrophic muscularis mucosae or muscularis propria. For renal pelvic tumors, in-situ extension of carcinoma into renal collecting ducts and renal tubules does not affect stage, while carcinoma invading into the renal parenchyma is pT3. Renal pelvic carcinoma that invades through the kidney into perinephric fat is pT4. Patients with upper tract urothelial carcinoma often present at higher stage compared to patients with urinary bladder carcinoma.^{3,9}

E. TNM and Stage Groupings

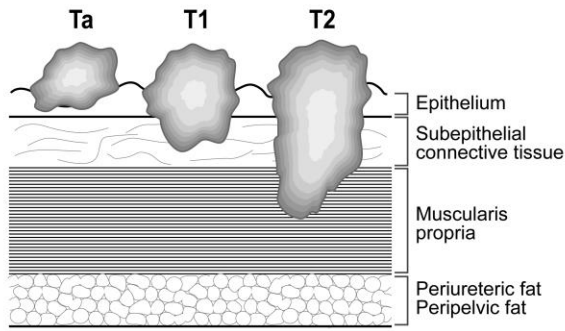
The TNM Staging System for carcinomas of the ureter and renal pelvis of the American Joint Committee on Cancer (AJCC) and the International Union Against Cancer (UICC) is recommended and shown below.¹³

By AJCC/UICC convention, the designation “T” refers to a primary tumor that has not been previously treated. The symbol “p” refers to the pathologic classification of the TNM, as opposed to the clinical classification, and is based on gross and microscopic examination. pT entails a resection of the primary tumor or biopsy adequate to evaluate the highest pT category, pN entails removal of nodes adequate to validate lymph node metastasis, and pM implies microscopic examination of distant lesions. Clinical classification (cTNM) is usually carried out by the referring physician before treatment during initial evaluation of the patient or when pathologic classification is not possible.

Pathologic staging is usually performed after surgical resection of the primary tumor. Pathologic staging depends on pathologic documentation of the anatomic extent of disease, whether or not the primary tumor has been completely removed. If a biopsied tumor is not resected for any reason (eg, when technically unfeasible) and if the highest T and N categories or the M1 category of the tumor can be confirmed microscopically, the criteria for pathologic classification and staging have been satisfied without total removal of the primary cancer.

Primary Tumor (T) (Figure 1)

The suffix “m” should be added to the appropriate T category to indicate multiple tumors. The suffix “is” may be added to any T to indicate the presence of associated carcinoma in situ.



T = pT

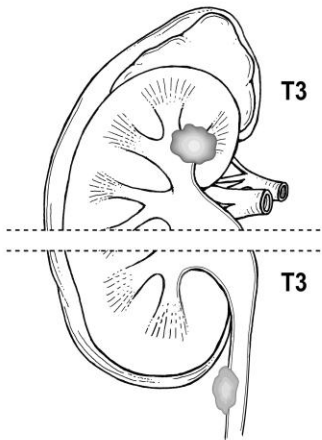


Figure 1. Depiction of pTa, pT1, pT2, and pT3.

Anatomic Stage/Prognostic Groups

Stage 0a	Ta	N0	M0 [#]
Stage 0is	Tis	N0	M0
Stage I	T1	N0	M0
Stage II	T2	N0	M0
Stage III	T3	N0	M0
Stage IV	T4	N0	M0
	Any T	N1,2,3	M0
	Any T	Any N	M1

[#] M0 is defined as no distant metastasis.

TNM Descriptors

For identification of special cases of TNM or pTNM classifications, the “m” suffix and “y” and “r” prefixes are used. Although they do not affect the stage grouping, they indicate cases needing separate analysis.

The “m” suffix indicates the presence of multiple primary tumors in a single site and is recorded in parentheses: pT(m)NM.

The “y” prefix indicates those cases in which classification is performed during or following initial multimodality therapy (ie, neoadjuvant chemotherapy, radiation therapy, or both chemotherapy and radiation therapy). The cTNM or pTNM category is identified

by a “y” prefix. The ycTNM or ypTNM categorizes the extent of tumor actually present at the time of that examination. The “y” categorization is not an estimate of tumor prior to multimodality therapy (ie, before initiation of neoadjuvant therapy).

The “r” prefix indicates a recurrent tumor when staged after a documented disease-free interval, and is identified by the “r” prefix: rTNM.

Additional Descriptors

Residual Tumor (R)

Tumor remaining in a patient after therapy with curative intent (eg, surgical resection for cure) is categorized by a system known as R classification, shown below.

RX	Presence of residual tumor cannot be assessed
R0	No residual tumor
R1	Microscopic residual tumor
R2	Macroscopic residual tumor

For the surgeon, the R classification may be useful to indicate the known or assumed status of the completeness of a surgical excision. For the pathologist, the R classification is relevant to the status of the margins of a surgical resection specimen. That is, tumor involving the resection margin on pathologic examination may be assumed to correspond to residual tumor in the patient and may be classified as macroscopic or microscopic according to the findings at the specimen margin(s).

F. Sections for Microscopic Evaluation

Tissue samples include ureteroscopic biopsies, needle biopsies, segmental ureterectomy specimens, and radical nephroureterectomy with urinary bladder cuff resection specimens.

Ureteroscopic biopsies are entirely submitted. Since these are often minute in size, one approach to processing is to submit the biopsy sample for cytology cell block preparation.

Needle core biopsies of renal masses, including urothelial carcinoma involving the kidney, should be completely submitted.

Segmental ureterectomy is performed for tumors of the proximal or mid ureter. The length and diameter of the intact ureter is recorded, with a search for a mass by palpation and visual inspection. Proximal and distal cross-section margins are taken, and the outer aspect of the ureter is inked. The ureter is then opened longitudinally and assessed for mucosal abnormalities. After overnight fixation in 10% formalin, sections are taken to demonstrate the deepest invasion of any lesion(s). At least 1 section of uninvolved ureter should be submitted.

Radical nephroureterectomy with bladder cuff. Gross examination and sampling should document the relationship of tumor to adjacent renal parenchyma, peripelvic fat, nearest soft tissue margin, and ureter. Sections of grossly unremarkable kidney, pelvis, and ureter should be obtained. The important urothelial margin is the urinary bladder cuff, which can be sampled as shave sections.

Lymph Nodes

Regional lymph nodes are not always submitted or identified in cases of resection,³ but evaluation of these nodes is important. Submit 1 section from each grossly positive lymph node. All other lymph nodes should be entirely submitted, as presence of nodal disease may be used as an indication for adjuvant therapy.

G. Margins

Resection margins, including those mentioned in Note **F**, should be carefully specified. Statements about deep soft tissue margins should specify whether peritoneal surfaces are involved by tumor. In renal pelvis, ureter, and nephroureterectomy specimens, the margins may include radial hilar soft tissue margin; bladder cuff; and ureteral, renal parenchymal, and Gerota's fascia margins, depending on the type of surgical specimen.

H. Lymph-Vascular Invasion

Urothelial carcinoma may invade blood vessels or lymphatic channels. This is an important prognostic factor in upper urinary tract urothelial carcinoma.^{3,14,15} In suspicious cases, blood vessels can be highlighted by immunohistochemical staining for factor VIII-related antigen, CD31 or CD34. Staining can help resolve the problem of differentiating lymphatic versus artifactual space formation by tumor cells, a frequent finding seen in urothelial tumors invading the lamina propria. Retraction artifact is also prominent in the "micropapillary variant" of urothelial carcinoma.

I. Pathologic Findings in Non-Neoplastic Kidney

It is important to recognize that medical kidney diseases may be present in non-neoplastic renal tissue in nephrectomy and nephroureterectomy specimens.^{16,17} Arterionephrosclerosis (or hypertensive nephropathy) and diabetic nephropathy are seen in approximately 30% and 20% of cases, respectively. Other medical renal diseases that have been identified include thrombotic microangiopathy, focal segmental glomerulosclerosis, and IgA nephropathy. The findings of greater than 20% global glomerulosclerosis or advanced diffuse diabetic glomerulosclerosis are predictive of significant decline in renal function 6 months after radical nephrectomy.¹⁷ Evaluation for medical renal disease should be performed in each case; PAS and/or Jones methenamine silver stains should be applied if necessary. Consultation with a nephropathologist should be pursued as needed.

References

1. Delahunt B, Amin MB, Hofstader F, Hartmann A, Tyczynski JE. Tumours of the renal pelvis and ureter. In: Eble JN, Sauter G, Epstein JI, Sesterhenn IA, eds. *World Health Organization Classification of Tumours: Pathology and Genetics of Tumours of the Urinary System and Male Genital Organs*. Lyon, France: IARC Press; 2004:150-153.
2. Murphy WM, Grignon DJ, Perlman EJ. Tumors of the ureters and renal pelvis. In: *Tumors of the Kidney, Bladder, and Related Urinary Structures*. AFIP Atlas of Tumor Pathology, Series 4. Washington, DC: American Registry of Pathology; 2004; 375-379.
3. Olgac S, Mazumdar M, Dalbagni G, Reuter VE. Urothelial carcinoma of the renal pelvis: a clinicopathologic study of 130 cases. *Am J Surg Pathol* 2004; 28:1545-1552.

4. Murphy WM. Diseases of the urinary bladder, urethra, ureters and renal pelvis. In: Murphy WM, ed. *Urological Pathology*. 2nd ed. Philadelphia, PA: WB Saunders Co; 1997:75-96.
5. Reuter VE. The urothelial tract: renal pelvis, ureter, urinary bladder, and urethra. In: Mills SE, Carter D, Greenson JK, Oberman HR, Reuter VE, Stoler MH, eds. *Diagnostic Surgical Pathology*. 4rd ed. Philadelphia, PA: Lippincott Williams and Wilkins; 2004:2035-2081.
6. Perez-Montiel D, Wakely PE, Hes O, Michal M, Suster S. High-grade urothelial carcinoma of the renal pelvis : clinicopathologic study of 108 cases with emphasis on unusual morphologic variants. *Mod Pathol*. 2006; 19:494-503.
7. Amin MB, Murphy WM, Reuter VE, et al. Controversies in the pathology of transitional cell carcinoma of the urinary bladder. Part I, Chapter 1. In: Rosen PP, Fechner RE, eds. *Reviews of Pathology*. Vol. 1. Chicago, IL: ASCP Press; 1996:1-39.
8. Epstein JI, Amin MB, Reuter VR, Mostofi FK, the Bladder Consensus Conference Committee. The World Health Organization/ International Society of Urological Pathology Consensus classification of urothelial (transitional cell) neoplasms of the urinary bladder. *Am J Surg Pathol*. 1998;22:1435-1448.
9. Catto JW, Yates DR, Rehman I, et al. Behavior of urothelial carcinoma with respect to anatomical location. *J Urol* 2007;177:1715-1720.
10. Gupta R, Paner GP, Amin MB. Neoplasms of the upper urinary tract: a review with focus on urothelial carcinoma of the pelvicalyceal system and aspects related to its diagnosis and reporting. *Adv Anat Pathol* 2008;15(3):127-139.
11. Margulis V, Shariat SF, Matin SF, et al. Outcomes of radical nephroureterectomy: a series from the Upper Tract Urothelial Carcinoma Collaboration. *Cancer*. 2009;115(6):1224-1233.
12. Reuter VE. Urinary bladder, ureter, and renal pelvis. In: Mills SE, ed. *Histology for Pathologists*. 3rd ed. Philadelphia, PA : Lippincott Williams and Wilkins; 2007: 909-922.
13. Edge SB, Byrd DR, Carducci MA, Compton CC, eds. *AJCC Cancer Staging Manual*. 7th ed. New York, NY: Springer; 2009.
14. Saito K, Kawakami S, Fujii Y, Sakura M, Masuda H, Kihara K. Lymphovascular invasion is independently associated with poor prognosis in patients with localized upper urinary tract urothelial carcinoma treated surgically. *J Urol*. 2007;178:2291-2296.
15. Kikuchi E, Margulis V, Karakiewicz PI, et al. Lymphovascular invasion predicts clinical outcomes in patients with node-negative upper tract urothelial carcinoma. *J Clin Oncol*. 2009;27(4):612-618.
16. Henriksen KJ, Meehan SM, Chang A. Non-neoplastic renal diseases are often unrecognized in adult tumor nephrectomy specimens: a review of 246 cases. *Am J Surg Pathol*. 2007;31:1703-1708.
17. Bijol V, Mendez GP, Hurwitz S, Rennke HG, Nose V. Evaluation of the non-neoplastic pathology in tumor nephrectomy specimens: predicting the risk of progressive failure. *Am J Surg Pathol*. 2006;30:575-584.