

# **Protocol for the Examination of Specimens from Patients with Ductal Carcinoma In Situ (DCIS) of the Breast**

**Protocol applies to DCIS without invasive carcinoma or microinvasion.**

---

## **Based on AJCC/UICC TNM, 6th edition**

Protocol web posting date: January 2009

Protocol effective date: September 2009

## **Procedures**

- Complete Excision (Less Than Total Mastectomy, Including Specimens Designated Biopsy, Lumpectomy, Quadrantectomy, and Partial Mastectomy; With or Without Axillary Contents)
- Mastectomy (Total, Modified Radical, Radical; With or Without Axillary Contents)

## **Authors**

Susan C. Lester, MD, PhD, FCAP

Department of Pathology, Brigham and Women's Hospital, Boston, Massachusetts

Shikha Bose, MD, FCAP

Department of Pathology and Laboratory Medicine, Cedars-Sinai Medical Center, Los Angeles, California

Yunn-Yi Chen, MD, PhD, FCAP

Department of Pathology, UCSF Medical Center, San Francisco, California

James L. Connolly, MD, FCAP

Department of Pathology, Beth Israel Deaconess Medical Center, Boston, Massachusetts

Monica de Baca, MD, FCAP

Physicians Laboratory, Sioux Falls, South Dakota

Patrick L. Fitzgibbons, MD, FCAP

Department of Pathology, St. Jude Medical Center, Fullerton, California

Daniel F. Hayes, MD, Department of Medical Oncology, University of Michigan Medical Center, Ann Arbor, Michigan

Celina Kleer, MD, FCAP

Department of Pathology, University of Michigan Medical Center, Ann Arbor, Michigan

Frances P. O'Malley, MD, FCAP

Department of Pathology and Laboratory Medicine, Mount Sinai Hospital, Toronto, University of Toronto, Ontario, Canada

David L. Page, MD, FCAP

Department of Pathology, Vanderbilt University Medical Center, Nashville, Tennessee

Barbara L. Smith, MD, PhD

Department of Surgical Oncology, Massachusetts General Hospital, Boston, Massachusetts

Donald L. Weaver, MD, FCAP

Department of Pathology, College of Medicine and Vermont Cancer Center, University of Vermont, Burlington, Vermont

Eric Winer, MD

Department of Medical Oncology, Dana-Farber Cancer Institute, Boston,  
Massachusetts

For the Members of the Cancer Committee, College of American Pathologists

© 2009 College of American Pathologists

## **Surgical Pathology Cancer Case Summary (Checklist)**

---

Protocol web posting date: January 2009

Protocol effective date: September 2009

**DCIS OF THE BREAST: Complete Excision (Less Than Total Mastectomy, Including Specimens Designated Biopsy, Lumpectomy, Quadrantectomy, and Partial Mastectomy; With or Without Axillary Contents) and Mastectomy (Total, Modified Radical, Radical; With or Without Axillary Contents)**

### **Check 1 Response Unless Otherwise Indicated**

#### **Specimen (Note A)**

- Partial breast  
 Total breast (including nipple and skin)  
 Other (specify): \_\_\_\_\_  
 Not specified

#### **Procedure (Note A)**

- Excision without wire-guided localization  
 Excision with wire-guided localization  
 Total mastectomy (including nipple and skin)  
 Other (specify): \_\_\_\_\_  
 Not specified

#### **Specimen Integrity**

- Single intact specimen (margins can be evaluated)  
 Multiple designated specimens (eg, main excisions and identified margins)  
 Fragmented (margins cannot be evaluated with certainty)

#### **Specimen Size (for excisions less than total mastectomy)**

Greatest dimension: \_\_\_ cm

\*Additional dimensions: \_\_\_ x \_\_\_ cm

Cannot be determined

#### **Lymph Node Sampling (check all that apply) (Note B)**

- No lymph nodes present  
 Sentinel lymph node(s)  
 Axillary dissection (partial or complete dissection)  
 Lymph nodes present within the breast specimen (ie, intramammary lymph nodes)

#### **Specimen Laterality**

- Right  
 Left  
 Not specified

\* Data elements with asterisks are not required. However, these elements may be clinically important but are not yet validated or regularly used in patient management.

**\*Tumor Site (check all that apply)**

- \*  Upper outer quadrant
- \*  Lower outer quadrant
- \*  Upper inner quadrant
- \*  Lower inner quadrant
- \*  Central
- \*  Nipple
- \*Position: \_\_\_\_\_ o'clock
- \*  Not specified

**Size (Extent) of DCIS (Note C and Figure)**

Estimated size (extent) of DCIS (greatest dimension using gross and microscopic evaluation): at least \_\_\_ cm

\*Additional dimensions \_\_\_ x \_\_\_ cm

\*Number of blocks with DCIS: \_\_\_

\*Number of blocks examined: \_\_\_

*Note: The size (extent) of DCIS is an estimation of the volume of breast tissue occupied by DCIS.*

**Histologic Type (Note D)**

\_\_\_ Ductal carcinoma in situ. Classified as Tis (DCIS) or Tis (Paget).

**\*Architectural Patterns (check all that apply) (Note E)**

- \*  Comedo
- \*  Paget disease (DCIS involving nipple skin)
- \*  Cribriform
- \*  Micropapillary
- \*  Papillary
- \*  Solid
- \*  Other (specify: \_\_\_\_\_)

**Nuclear Grade (Note F)**

- \_\_\_ Grade I (low)
- \_\_\_ Grade II (intermediate)
- \_\_\_ Grade III (high)

**Necrosis (Note G)**

- \_\_\_ Not identified
- \_\_\_ Present, focal (small foci or single cell necrosis)
- \_\_\_ Present, central (expansive "comedo" necrosis)

\* Data elements with asterisks are not required. However, these elements may be clinically important but are not yet validated or regularly used in patient management.

**Margins (check all that apply) (Note H)** Margins cannot be assessed Margin(s) uninvolved by DCIS

Distance from closest margin: \_\_\_ mm

\*Specify margins:

\*Distance from superior margin: \_\_\_ mm

\*Distance from inferior margin: \_\_\_ mm

\*Distance from medial margin: \_\_\_ mm

\*Distance from lateral margin: \_\_\_ mm

\*Distance from anterior margin: \_\_\_ mm

\*Distance from posterior margin: \_\_\_ mm

 Margin(s) positive for DCIS

\*Specify which margin(s) and extent of involvement:

\* \_\_\_ Superior margin

\* \_\_\_ Focal

\* \_\_\_ Minimal/moderate

\* \_\_\_ Extensive

\* \_\_\_ Inferior margin

\* \_\_\_ Focal

\* \_\_\_ Minimal/moderate

\* \_\_\_ Extensive

\* \_\_\_ Medial margin

\* \_\_\_ Focal

\* \_\_\_ Minimal/moderate

\* \_\_\_ Extensive

\* \_\_\_ Lateral margin

\* \_\_\_ Focal

\* \_\_\_ Minimal/moderate

\* \_\_\_ Extensive

\* \_\_\_ Anterior margin

\* \_\_\_ Focal

\* \_\_\_ Minimal/moderate

\* \_\_\_ Extensive

\* \_\_\_ Posterior margin

\* \_\_\_ Focal

\* \_\_\_ Minimal/moderate

\* \_\_\_ Extensive

**\*Treatment Effect: Response to Presurgical (Neoadjuvant) Therapy (Note I)**

\* \_\_\_ No known presurgical therapy

\* \_\_\_ No definite response to presurgical therapy

\* \_\_\_ Probable or definite response to presurgical therapy

**Lymph Nodes (required only if lymph nodes are present in the specimen) (Note J)**

Number of sentinel nodes examined: \_\_\_\_\_

Total number of nodes examined (sentinel and nonsentinel): \_\_\_\_\_

Number of lymph nodes with macrometastases (&gt;0.2 cm): \_\_\_\_\_

Number of lymph nodes with micrometastases (&gt;0.2 mm to 0.2 cm): \_\_\_\_\_

Number of lymph nodes with isolated tumor cells ( $\leq$  to 0.2 mm): \_\_\_\_\_

Size of largest metastatic deposit (if present): \_\_\_\_\_

\*Extranodal extension:

\* \_\_\_\_\_ Present

\* \_\_\_\_\_ Not identified

*\*Method of Evaluation of Sentinel Lymph Nodes (check all that apply)*

\* \_\_\_\_\_ Hematoxylin and eosin (H&amp;E), 1 level

\* \_\_\_\_\_ H&amp;E, multiple levels

\* \_\_\_\_\_ Immunohistochemistry

\* \_\_\_\_\_ Other (specify): \_\_\_\_\_

**Pathologic Staging (pTNM) (Note K)**TNM Descriptors (required only if applicable)

\_\_\_\_\_ r (recurrent)

\_\_\_\_\_ y (post-treatment)

Primary Tumor (pT)

\_\_\_\_\_ pTis (DCIS): Ductal carcinoma in situ

\_\_\_\_\_ pTis (Paget): Paget disease of the nipple (with or without underlying DCIS in the breast) without invasive carcinoma.

*Note: If there has been a prior core needle biopsy, the pathologic findings from the core, if available, should be incorporated in the T classification. If invasive carcinoma or microinvasion were present on the core, the protocol for invasive carcinomas of the breast<sup>1</sup> should be used and should incorporate this information.*Regional Lymph Nodes (pN) (choose a category based on data supplied with specimen; immunohistochemistry and molecular studies are not required)*Modifier (required only if applicable)*

\_\_\_\_\_ (sn) Only sentinel node(s) evaluated

Category (pN)

\_\_\_\_\_ pNX: Cannot be assessed (previously removed or not removed for pathologic study)

\_\_\_\_\_ pN0: No regional lymph node metastasis histologically (ie, none greater than 0.2 mm), no examination for isolated tumor cells (ITCs)

\_\_\_\_\_ pN0(i-): No regional lymph node metastasis histologically, negative morphologic (any morphologic technique, including hematoxylin-eosin and immunohistochemistry) findings for ITCs

\* Data elements with asterisks are not required. However, these elements may be clinically important but are not yet validated or regularly used in patient management.

- \_\_\_ pN0(i+): No regional lymph node metastasis histologically, positive morphologic (any morphologic technique, including hematoxylin-eosin and immunohistochemistry) findings for ITCs, no ITC cluster greater than 0.2 mm
- \_\_\_ pN0(mol-): No regional lymph node metastasis histologically, negative nonmorphologic (molecular) findings for ITCs
- \_\_\_ pN0(mol+): No regional lymph node metastasis histologically, positive nonmorphologic (molecular) findings for ITCs
- \_\_\_ pN1mi: Micrometastasis (>0.2 mm, none >2.0 mm)
- \_\_\_ pN1a: Metastasis in 1 to 3 axillary lymph nodes (at least 1 tumor deposit >2.0 mm; do not include lymph nodes with isolated tumor cells)
- \_\_\_ pN2a: Metastasis in 4 to 9 axillary lymph nodes (at least 1 tumor deposit >2.0 mm; do not include lymph nodes with isolated tumor cells)
- \_\_\_ pN3a: Metastasis in 10 or more axillary lymph nodes (at least 1 tumor deposit >2.0 mm; do not include lymph nodes with isolated tumor cells), or metastasis to the infraclavicular lymph nodes
- \_\_\_ Other: If internal mammary nodes or supraclavicular nodes have been sampled, other nodal classifications may apply.

**Distant Metastasis (pM)**

- \_\_\_ Not applicable
- \_\_\_ pM1: Distant metastasis

\*Specify site(s), if known: \_\_\_\_\_

*Note: The presence of distant metastases in a case of DCIS would be very unusual. Additional sampling to identify invasive carcinoma in the breast or additional history to document a prior or synchronous invasive carcinoma is advised in the evaluation of such cases.*

**\*Additional Pathologic Findings (Note L)**

\*Specify: \_\_\_\_\_

**\*Ancillary Studies**

\***Estrogen Receptor** (results of special studies performed on this specimen or a prior core needle biopsy) **(Note M)**

- \* \_\_\_ Immunoreactive tumor cells present
- \* \_\_\_ No immunoreactive tumor cells present
- \* \_\_\_ Pending
- \* \_\_\_ Not performed
- \* \_\_\_ Other (specify): \_\_\_\_\_

\*Name of antibody: \_\_\_\_\_

\*Name of vendor: \_\_\_\_\_

\*Type of fixative: \_\_\_\_\_

\*Progesterone Receptor (results of special studies performed on this specimen or a prior core needle biopsy) **(Note M)**

- \*  Immunoreactive tumor cells present
- \*  No immunoreactive tumor cells present
- \*  Pending
- \*  Not performed
- \*  Other (specify): \_\_\_\_\_

\*Name of antibody: \_\_\_\_\_

\*Name of vendor: \_\_\_\_\_

\*Type of fixative: \_\_\_\_\_

\***Microcalcifications (check all that apply) (Note N)**

- \*  Not identified
- \*  Present in DCIS
- \*  Present in non-neoplastic tissue
- \*  Present in both DCIS and non-neoplastic tissue

\***Clinical History (check all that apply) (Note O)**

The current clinical/radiologic breast findings for which this surgery is performed include:

- \*  Palpable mass
- \*  Radiologic finding
  - \*  Mass or architectural distortion
  - \*  Calcifications
  - \*  Other (specify): \_\_\_\_\_
- \*  Nipple discharge
- \*  Other (specify): \_\_\_\_\_
- \*  Prior history of breast cancer
  - \*Specify site, diagnosis, and prior treatment: \_\_\_\_\_
- \*  Prior neoadjuvant treatment for this diagnosis of DCIS
  - \*Specify type: \_\_\_\_\_

\***Comment(s)**

## Explanatory Notes

### A. Breast Specimens and Breast Procedures

#### Breast Specimens

The following types of breast specimens and procedures may be reported with the checklist:

**Excisions.** Removal of breast tissue without the intent of removing the entire breast. The nipple is only rarely removed with excisions. Excisions include specimens designated biopsies, partial mastectomies, lumpectomies, and quadrantectomies.

- Wire-guided localization excisions: If a nonpalpable lesion is detected by mammography, ultrasound, or magnetic resonance imaging (MRI), a wire is placed to identify the location of the lesion for the surgeon. Mammography or ultrasound should be used to document the presence of the targeted lesion in the excised tissue. The specimen radiograph (if performed) and the results of the radiologic evaluation should be available to the pathologist. Because MRI utilizes vascular uptake, it is not possible to image the specimen by using this technique to document the presence and location of the lesion.
- Excisions without wire localization: These excisions are generally performed for palpable masses or to excise major ducts behind the nipple to evaluate nipple discharge.

**Total Mastectomy.** Removal of all breast tissue, including the nipple and areola.

- Simple mastectomy: This procedure consists of a total mastectomy without removal of axillary lymph nodes.
- Skin-sparing mastectomy: This is a total mastectomy with removal of the nipple and only a narrow surrounding rim of skin.
- Modified radical mastectomy: This procedure consists of a total mastectomy and an axillary dissection. In the checklist, the breast and lymph node specimens are documented separately.
- Radical mastectomy: This procedure consists of a total mastectomy with removal of the pectoralis muscles and currently is performed only rarely. This type of specimen and procedure can be indicated on the checklist as "Other."

The following types of specimens should not be reported using this checklist:

- Very small incisional biopsies (including core needle biopsies).
- Excisions after a core needle biopsy showing invasive carcinoma or DCIS with microinvasion (invasion measuring  $\leq 0.1$  cm). This type of case should be reported by using the protocol for invasive carcinoma of the breast,<sup>1</sup> and the report should incorporate information from the prior needle biopsy.
- Reexcision of a biopsy site or mastectomy after an excision, unless a carcinoma of a higher T category than that in prior specimens is present. If invasive carcinoma is found on a subsequent excision, the protocol for invasive carcinomas of the breast<sup>1</sup> should be used.

#### Specimen Sampling

Specimen sampling for specimens with DCIS has the following goals<sup>2-6</sup>:

- The clinical or radiologic lesion for which the surgery was performed must be examined microscopically. If the lesion is a nonpalpable imaging finding, the specimen radiograph and/or additional radiologic studies may be necessary to

identify the lesion. When practical, the entire specimen should be submitted in a sequential fashion for histologic examination. If this is not possible, at least the entire region of the targeted lesion should be examined microscopically. If DCIS, lobular carcinoma in situ (LCIS), or atypical hyperplasia is identified, all fibrous tissue should be examined.<sup>2</sup>

- All other gross lesions noted in the specimen must be sampled.
- The margins must be evaluated for involvement by DCIS. If the specimen is received sectioned or fragmented, this should be noted, as this will limit the ability to evaluate the size of lesions and the status of margins. If the specimen is an incisional biopsy, margins need not be evaluated.

For specimens with a known diagnosis of DCIS (eg, by prior core needle biopsy) it is highly recommended that the entire specimen is examined using serial sequential sampling to exclude the possibility of invasion, to completely evaluate the margins, and to aid in determining extent.<sup>7-9</sup> If an entire excisional specimen or grossly evident lesion is not examined microscopically, it is helpful to note the approximate percentage of the specimen or lesion that has been examined.

Carcinomas present in excisions removed for lesions seen best by MRI studies are generally not grossly evident and not seen on specimen radiography.<sup>10</sup> Complete microscopic evaluation of all tissue is necessary to detect all cancers in these specimens.

Recording the specimen size is important, as the volume of tissue excised has been associated with the likelihood of recurrence.<sup>11</sup>

Tissue may be taken for research studies or assays that do not involve the histologic examination of the tissue (eg, reverse transcription-polymerase chain reaction or RT-PCR) only when taken in such a way to be able to evaluate the tissue for small areas of invasion. For example, a thin slice of tissue taken for research studies should be matched with an adjacent slice of tissue that will be examined microscopically.

## **B. Lymph Node Sampling**

Patients with DCIS may have lymph nodes sampled in the following situations:

- Extensive DCIS: Patients with extensive DCIS are more likely to have areas of invasion and it may be difficult or impractical to examine all involved areas of the breast microscopically.<sup>12-14</sup> A lymph node with a macrometastasis would indicate an occult area of invasion.
- Pathologic findings on a prior needle biopsy or excision raising concern for invasion or microinvasion (invasion measuring  $\leq 0.1$  cm in size): If invasion has been documented, the checklist for invasive carcinoma of the breast<sup>1</sup> should be used.
- Imaging findings (eg, an irregular mass) or clinical findings (eg, a large palpable mass) that increase the likelihood that stromal invasion is present.<sup>13</sup>
- Planned mastectomy: The additional sampling of low lymph nodes or a sentinel lymph node does not result in increased morbidity. If the node or nodes are negative, and invasive cancer is found, another surgical procedure for node sampling can be avoided.

Most tumor cells in lymph nodes of patients with DCIS would be classified as isolated tumor cells.<sup>15,16</sup> If a larger nodal metastasis is found and the breast tissue has not been

entirely submitted for microscopic examination, additional sampling should be considered to attempt to identify invasive carcinoma.<sup>12,14</sup>

Grossly uninvolved nodes should be submitted in their entirety for histologic examination, whereas a representative section of a grossly positive node may be submitted. Small nodes (eg, 0.2 to 0.3 cm) may be submitted intact, but larger nodes should be thinly sectioned. If nodes are inked different colors before slicing, an accurate count of positive nodes can be obtained when slices of multiple nodes are included in the same cassette. An accurate assessment of the number of positive lymph nodes is a critical prognostic indicator.

Sentinel lymph nodes are identified as such by the surgeon, generally by uptake of radiotracer or dye.

### **C. Size (Extent) of DCIS**

Although not required for pT classification or stage assignment, the size (extent) of DCIS is an important factor in patient management.<sup>5,17</sup> Extent (as determined by a number of different methods) is correlated with the likelihood of residual disease after re-excision,<sup>18-21</sup> close or positive margins,<sup>18,21</sup> local recurrence,<sup>22-24</sup> and the possibility of missed areas of invasion.<sup>13,14</sup> Extent is not as important for predicting local recurrence when wide margins are obtained.<sup>22,23,25</sup>

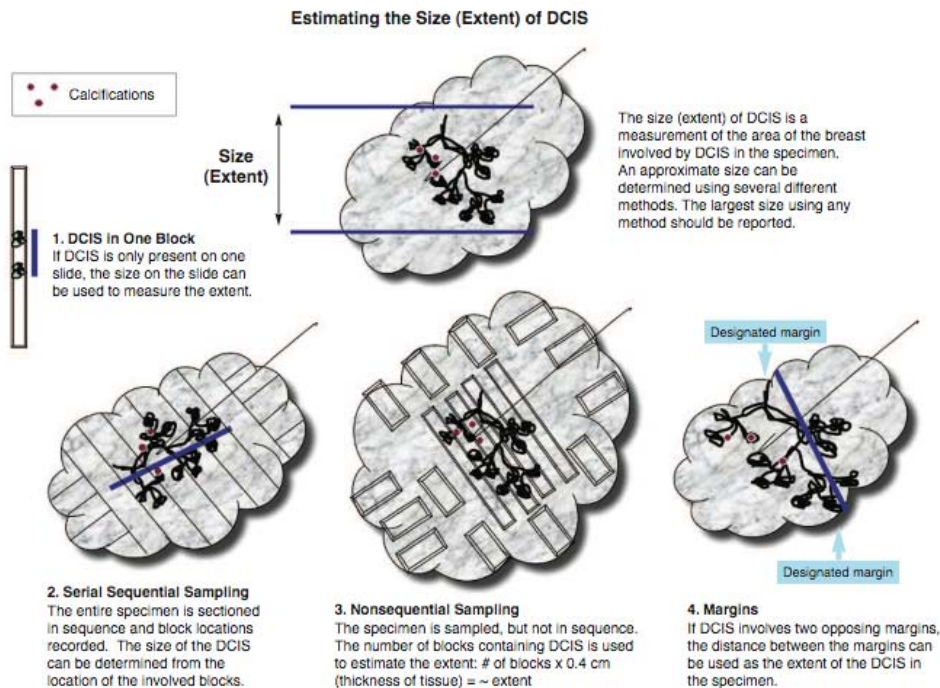
Extent is an estimation of the volume of breast tissue involved by DCIS. Mammographic assessment of DCIS, usually based on distribution of calcifications, frequently underestimates, and sometimes overestimates, the extent of DCIS. Precise measurement of extent is generally difficult or impossible for the following reasons<sup>26</sup>:

- DCIS involves the ductal system in a complex 3-dimensional branching pattern that is usually only apparent by microscopic examination. When gross findings are present (eg, areas of tissue thickening and/or punctate necrosis), they often do not correspond to the entire area of involvement.
- The ductal system and surrounding tissue is highly compressible (a fact any woman who has undergone mammography can verify). Specimens may be distorted during surgery or specimen processing or compressed during specimen radiography.<sup>27,28</sup>
- Diagnostic gaps in ductal involvement may be present (particularly for low-grade DCIS)
- DCIS is often not removed in one excision and may be present in multiple specimens from one surgical procedure or in multiple specimens from multiple procedures. This is more likely in cases of large areas of involvement.

The mean or median extent of DCIS is 1.4 to 2.7 cm<sup>8,9,18,21</sup> but ranges from 0.1 cm to extensive involvement of all 4 quadrants of the breast. Although a precise measurement is often not possible, an estimate of the extent of DCIS is clinically important (Table 1).

**Table 1. Extent of Ductal Carcinoma In Situ (DCIS) and Clinical Significance**

Size	Extent
Up to 2 cm	Breast conservation with wide negative margins can be achieved in most women. Microscopic examination of the entire area involved by DCIS is recommended and should be possible in most cases. This will require complete microscopic examination of smaller biopsies, or sampling of large excisions or mastectomies to include all areas likely to contain DCIS (eg, tissue with radiologic calcifications or grossly abnormal tissue).
>2-4 cm	Wide negative margins may be difficult to achieve in some women with breast-conserving surgery. Microscopic examination of the entire area involved by DCIS is recommended but may be difficult to achieve in some cases. This will require complete microscopic examination of smaller biopsies or sampling of large excisions or mastectomies to include all areas likely to contain DCIS (eg, tissue with radiologic calcifications or grossly abnormal tissue).
>4 cm	Breast conservation with wide negative margins may be impossible to achieve in some women. Microscopic examination of the entire area involved by DCIS is recommended but may be impractical in some cases. This will require complete microscopic examination of smaller biopsies or selective sampling of large excisions or mastectomies to include areas likely to contain DCIS (eg, tissue with radiologic calcifications or grossly abnormal tissue). There is a possibility of undetected areas of invasion if the area involved by DCIS is not completely examined. Lymph node sampling may be recommended.



There are multiple methods for estimating the extent of DCIS (see Figure):

- **DCIS in One Block:** The area involved by DCIS can be measured from a single slide, if DCIS is present in only one block. If separate foci are present, the largest distance between foci should be reported. This method will underestimate the extent of DCIS when multiple blocks are involved, and should not be used in such cases.<sup>8</sup>
- **Serial Sequential Sampling:** The entire specimen is blocked out in such a way that the location of each block can be determined. The extent of the DCIS can be calculated by using a diagram of the specimen, the thickness of the slices, and the location of the involved blocks.<sup>7-9</sup> This method is recommended for all excisions likely to harbor DCIS or with previously diagnosed DCIS (eg, by diagnosis on a prior core needle biopsy).
- **Nonsequential Sampling:** The number of blocks involved by DCIS is correlated with the extent of DCIS up to 4 cm.<sup>8</sup> Multiplying the number of blocks involved by DCIS by the approximate width of a tissue section gives an estimate of the extent. In 2 studies, multiplying by 0.3 cm underestimated the extent of DCIS, and multiplying by 0.5 cm may overestimate the extent.<sup>8,9</sup> Therefore, multiplying by 0.4 cm is recommended unless there is additional information that a different number would yield a more accurate result. This method may underestimate extent if not all areas of DCIS are sampled. Therefore, it is recommended that all tissue likely to be involved by DCIS be sampled (eg, all grossly abnormal tissue and all tissue with radiologically suspicious calcifications). When feasible, the entire specimen should be examined microscopically.

This method may result in a larger estimation of extent than the serial sequential sampling method when DCIS is present in a large volume of tissue in 3 dimensions rather than in a predominantly linear distribution. The best estimate for correlation with outcomes (eg, residual disease or recurrence) will require further studies.

This method can be applied to any specimen and will give a better estimation of extent than measuring extent on a single slide when multiple blocks contain DCIS.

- **Margins:** If DCIS involves or is close to 2 opposing margins, the distance between the margins can be used as the extent of the DCIS within the specimen.
- **Gross Lesions:** In some cases of high-grade DCIS, there may be a gross lesion that can be measured. Confirmation of the gross size must be confirmed by microscopic evaluation.

The largest estimate obtained using any of these methods should be used to report the estimated size (extent) of the DCIS.

#### D. Histologic Type

This protocol applies only to cases of DCIS. The protocol for invasive carcinoma of the breast<sup>1</sup> applies if invasion or microinvasion (less than or equal to 0.1 cm) is present. This protocol should not be used for classic/typical LCIS (eg, extent and margins are not

generally reported) but can be used for rare difficult to classify cases of carcinoma in situ with features of both DCIS and LCIS (eg, architectural patterns of both DCIS and LCIS or cytologic features of LCIS (without expression of e-cadherin), but with high-grade nuclei and/or necrosis). In some cases, clinicians may choose to treat such cases as DCIS.

When DCIS involves nipple skin, the tumor cells may disrupt epithelial tight junctions, resulting in seepage of extracellular fluid and formation of the scale crust recognized clinically as Paget disease of the nipple. If there is no associated invasive carcinoma, the cancer is classified as DCIS (ie, Tis (Paget)). The majority of these cases are strongly positive for HER2.

In some cases, immunohistochemical studies for myoepithelial cells may be helpful to confirm a diagnosis of DCIS and to exclude invasion.<sup>6,29</sup>

### E. Architectural Pattern

The architectural pattern has been reported traditionally for DCIS.<sup>3-5</sup> However, nuclear grade and the presence of necrosis are more predictive of clinical outcome.

### F. Nuclear Grade

The nuclear grade of DCIS is determined using 6 morphologic features (Table 2).<sup>4,30</sup>

**Table 2. Nuclear Grade of Ductal Carcinoma In Situ\***

Feature	Grade I (Low)	Grade II (Intermediate)	Grade III (High)
Pleomorphism	Monotonous (monomorphic)	Intermediate	Markedly pleomorphic
Size	1.5X to 2X the size of a normal RBC or a normal duct epithelial cell nucleus	Intermediate	>2X the size of a normal RBC or a normal duct epithelial cell nucleus
Chromatin	Usually diffuse, finely dispersed chromatin	Intermediate	Usually vesicular with irregular chromatin distribution
Nucleoli	Only occasional		Prominent, often multiple
Mitoses	Only occasional	Intermediate	May be frequent
Orientation	Polarized toward luminal spaces	Intermediate	Usually ont polarized toward the luminal space

\* RBC indicated red blood cell.

### G. Necrosis<sup>4</sup>

The presence of necrosis is correlated with the finding of mammographic calcifications (ie, most areas of necrosis will calcify). DCIS that presents as mammographic calcifications often recurs as calcifications. Necrosis can be classified as follows:

- **Central (“comedo”)**: The central portion of an involved ductal space is replaced by an area of expansive dirty necrosis that is easily detected at low magnification. Ghost cells and karyorrhectic debris are generally present. Although central necrosis is generally associated with high-grade nuclei (ie, comedo DCIS), it can also occur with DCIS of low or intermediate nuclear grade. This type of necrosis often correlates with a linear and/or branching pattern of calcifications on mammography.
- **Focal (punctate)**: Small foci, indistinct at low magnification, or single cell necrosis.

Necrosis should be distinguished from secretory material, which can also be associated with calcifications, cytoplasmic blebs, and histiocytes, but does not include nuclear debris.

## H. Margins

Whenever feasible, the specimen should be oriented in order to identify specific margins.

Margins may be identified by sutures or clips placed on the specimen surface or by other means of communication between surgeon and pathologist and should be documented in the pathology report. Margins can be identified microscopically in several ways, including the use of multiple colored inks, by submitting the margins in specific cassettes, or by the surgeon submitting each margin as a separately excised specimen. Inks should be applied to the surface of the specimen, taking care to avoid penetration into the specimen.

If margins are sampled with perpendicular sections, the pathologist should report the distance from the DCIS to the closest margin, when possible. Due to the growth pattern of DCIS in the ductal system, a negative but close margin does not ensure the absence of DCIS in the adjacent tissue.

A positive margin requires ink on DCIS. If the specimen is oriented, the specific site(s) of involvement (eg, superior margin) should also be reported.

The deep margin may be at muscle fascia. If so, the likelihood of additional breast tissue beyond this margin (and therefore possible involvement by DCIS) is extremely small. A deep muscle fascial margin (eg, on a mastectomy specimen) is unlikely to have clinical significance.

A superficial (generally anterior) margin may be immediately below the skin, and there may not be additional breast tissue beyond this margin. However, some breast tissue can be left in skin flaps, and the likelihood of residual breast tissue is related to the thickness of the flap.<sup>31</sup>

Specimen radiography is important to assess the adequacy of excision. Compression of the specimen should be minimized, as it can severely compromise the ability to assess the distance of the DCIS from the surgical margin.<sup>27</sup> Mechanical compression devices should be used with caution and preferably reserved for nonpalpable lesions that require this technique for imaging (eg, microcalcifications).

If DCIS is present at the margin, the extent of margin involvement is associated with the likelihood of residual disease<sup>19,20</sup>:

- Focal (eg, DCIS at the margin in a <0.1 cm area in 1 block)
- Minimal/moderate (between focal and extensive)
- Extensive (eg, DCIS at the margin in an area  $\geq$ 1.5 cm or in 5 or more low-power fields and/or in 8 or more blocks)

## I. Neoadjuvant Therapy

Patients may be treated with endocrine therapy, chemotherapy, or HER-2-targeted therapy prior to surgical excision, either as part of a protocol or during treatment of a contralateral carcinoma. It has been observed after treatment of women with invasive carcinoma that the invasive carcinoma may respond to a greater extent than the

accompanying DCIS. The histologic changes occurring in DCIS after treatment have not been well described and will likely vary with the specific agents used. Comparison to a pretreatment specimen is necessary to attribute histologic changes to the effects of treatment. The significance of histologic changes in DCIS is unknown.

If the patient had invasive carcinoma prior to treatment, but only DCIS after treatment, additional classification systems are available to evaluate residual carcinoma in the breast and lymph nodes.<sup>32</sup>

## **J. Lymph Nodes**

### **Reporting Lymph Nodes**

The pathology report should state the total number of lymph nodes examined (including the number of sentinel nodes), the number of nodes with metastases, and the greatest dimension of the largest metastatic focus. If a patient has at least 1 macrometastasis, only nodes with micro and macrometastases are included for the total number of involved nodes for N classification.<sup>33</sup> Nodes with isolated tumor cells are not included in this count.

One section from grossly involved nodes may be examined. All other lymph nodes should be thinly sectioned and entirely submitted for microscopic evaluation. A single H&E section from each lymph node block is considered sufficient for routine evaluation. If additional studies are performed, these should be documented (ie, additional H&E levels or immunohistochemical studies). The presence of extranodal tumor extension should be included in the pathology report because it may be associated with a higher frequency of axillary recurrence.

If lymph node sampling has not been performed or if information about a prior lymph node sampling is unavailable, "X" is used rather than a number in the N designation. A pN classification requires removal of lymph nodes with pathologic examination.

The classification is based on axillary lymph node dissection with or without sentinel lymph node dissection. Classification based solely on sentinel lymph node dissection without subsequent axillary dissection is designated (sn) for "sentinel node," eg, pN0(i+)(sn).

Isolated tumor cells (ITCs) are defined as single tumor cells or small cell clusters not greater than 0.2 mm.<sup>34-36</sup> They may be detected by routine histologic examination or by immunohistochemical (IHC) or molecular methods. ITCs do not usually show evidence of malignant activity (eg, proliferation or stromal reaction). Micrometastases may show histologic evidence of malignant activity (eg, proliferation or stromal reaction).

Almost all tumor cells present in lymph nodes of patients with DCIS are isolated tumor cells. Isolated tumor cells detected in cases of DCIS have not been shown to have prognostic importance.<sup>15,16</sup> If a larger metastasis is found, additional tissue sampling and review of slides are helpful to determine if an area of invasion is present.<sup>14</sup>

## **K. Pathologic Staging**

The TNM staging system for carcinoma of the breast of the American Joint Committee on Cancer (AJCC) and the International Union Against Cancer (UICC) is recommended.<sup>33,37</sup> Although the pathologist provides information about the individual T

and N categories based on examination of the surgical specimen, the treating physician has the responsibility for grouping the TNM categories into a stage of disease.

By AJCC/UICC convention, the designation “T” refers to a primary tumor that has not been previously treated and pM implies microscopic examination of distant lesions. Clinical classification (cTNM) is usually carried out by the referring physician before treatment during initial evaluation of the patient or when pathologic classification is not possible.

Pathologic staging is usually performed after surgical resection of the primary tumor. Pathologic staging depends on pathologic documentation of the anatomic extent of disease and whether or not the primary tumor has been completely removed. If a biopsied tumor is not resected for any reason (eg, when technically not feasible), but the highest T and N categories or the M1 category of the tumor can be confirmed microscopically, then the criteria for pathologic classification and staging have been satisfied without total removal of the primary cancer.

### **TNM Descriptors**

The symbol “p” refers to the pathologic classification of the TNM, as opposed to the clinical classification, and is based on gross and microscopic examination. pT entails a resection of the primary tumor or biopsy adequate to evaluate the highest pT category.

For identification of special cases, the “y,” and “r,” prefixes are used. Although they do not change the stage grouping, the “y” and “r” prefixes indicate cases needing separate analysis.

#### ypTNM

The “y” prefix is used for those cases in which classification is performed during or following initial therapy prior to surgical removal of the tumor (ie, neoadjuvant chemotherapy, radiation therapy, endocrine therapy, or combinations of these treatments). The ypT categorizes the extent of tumor actually present at the time of the examination. The “y” categorization is not an estimate of tumor prior to therapy (ie, before initiation of neoadjuvant therapy).

#### rpTNM

The “r” prefix indicates a recurrent tumor when staged after a documented disease-free interval.

### **Distant Metastasis**

In general, the presence of distant metastases are assessed using clinical methods or by other types of biopsies (eg, liver biopsies, lung biopsies). Therefore, no M classification should be provided when only a breast specimen and regional nodes are evaluated.

### **L. Additional Pathologic Findings**

In some cases, other pathologic findings are important for the clinical management of patients.

If the biopsy was performed for a benign lesion and the DCIS is an incidental finding, this should be documented. An example would be the finding of DCIS in an excision for a palpable fibroadenoma.

Peritumoral vascular invasion is a very rare finding in association with DCIS alone. Additional sampling should be considered to attempt to identify an area of invasion. If there has been prior surgery or needle biopsy, the possibility of artifactual displacement of epithelial cells into lymphatics should be considered. Lymph node biopsy may be performed in patients with DCIS and lymphovascular invasion.

If there has been a prior core needle biopsy or incisional biopsy, the biopsy site should be sampled and documented in the report. If the intention was to completely re-excise a prior surgical site, the report should document biopsy changes at the margin that could indicate an incomplete excision. This protocol should only be used for re-excisions that reveal the largest extent of DCIS.

### **M. Hormone Receptors**

The hormone receptor status of DCIS may be evaluated for multiple reasons. The primary use of this information is to determine if patients with DCIS would benefit from hormonal therapy.

Two studies have addressed outcomes for patients with DCIS undergoing hormonal therapy, and both studies showed that fewer women in the tamoxifen treated group developed subsequent breast cancers: 18% versus 14% in the UK/ANZ study<sup>38</sup> and 13.4% versus 8.2% in the NSABP B24 study.<sup>39</sup> However, this result was only statistically significant in the NSABP study. It is possible that the younger age of the patients in this study could have influenced these results, as a smaller benefit was observed in women over the age of 50. There was no benefit for survival in either study.

A subsequent analysis of estrogen receptor (ER) status for DCIS in a subset of patients in the NSABP trial showed that the reduction in subsequent breast cancers was greatest for women with ER-positive DCIS treated with tamoxifen.<sup>40</sup> Little benefit was found in women with ER-negative DCIS, but due to the small number of events, a small clinically significant benefit was not excluded.

The Update Committee of the American Society of Clinical Oncology concluded that current data are insufficient to make a general recommendation for the use of ER status of DCIS to make decisions about tamoxifen treatment.<sup>41</sup> National Comprehensive Cancer Network practice guidelines include determination of ER status as part of the work-up of DCIS.<sup>42</sup> Although progesterone receptor (PR) is often ordered in conjunction with ER, there are almost no data on the association of PR status and DCIS. As a result, many institutions do not assess PR on cases of DCIS. In addition to considerations for hormonal treatment, information about hormone receptor and HER2 status in DCIS may be useful for other reasons in some settings. As in invasive carcinoma, these markers identify different types of DCIS, including "ER-positive," "HER2-positive," and "triple-negative" cancers.<sup>43,44</sup> For invasive carcinomas, these immunoprofiles identify groups with different prognoses and response to different types of treatments. The usefulness of these markers for determining outcome or response to treatment for DCIS is under investigation. Some ongoing treatment protocols require marker information in DCIS for entry. In addition, recurrent carcinomas, in general, have the same immunoprofile as the prior DCIS.<sup>45-47</sup> Therefore, this information may be helpful for some patients and clinicians in making decisions about local treatment that could affect the likelihood of such a recurrence.

Because marker status in DCIS is used primarily for clinical purposes and not for diagnosis (except in rare cases to help distinguish Toker cells in nipple skin from the cells of an underlying DCIS resulting in Paget disease), the decision to perform these markers should be made in conjunction with the clinicians who will use this information.

The results of hormone receptor stains performed on a prior core needle biopsy can be included in the checklist for an excisional specimen. If the result of the study on the core needle biopsy is negative, repeat studies on a larger area of DCIS in the excisional biopsy should be considered.

Most (75% to 80%) cases of DCIS are ER positive, with strong immunoreactivity in the majority of cells (Table 3). Almost all cases of ER-negative DCIS are of high nuclear grade, and many are associated with necrosis. In some cases, it may be difficult to distinguish rare positive tumor cells from intermingled normal epithelial cells.

**Table 3. Classification of Immunohistochemical Results for Estrogen and Progesterone Receptor for Ductal Carcinoma In Situ**

Category	Comments
Immunoreactive tumor cells present	In most cases of DCIS, the majority of tumor cells will be positive for ER. In unusual cases, only rare cells may be positive (<10%). Although the clinical significance of this finding is currently unknown, it may be of value to include this finding in a note.
No immunoreactive tumor cells present	This category should be used for cases of DCIS with no cells showing immunoreactivity for hormone receptors.
Pending	Testing has been ordered and will be reported at a later date.
Not performed	Hormone receptor status may not be required for the care of some patients (eg, bilateral mastectomies, patients with contralateral ER positive invasive carcinoma).
Other	This category should be explained with a note and may include the following: <ul style="list-style-type: none"> <li>• Insufficient DCIS on deeper levels</li> <li>• Immunohistochemical studies were performed on a prior core needle biopsy, but the results are not available</li> </ul>

In addition to the interpretation, each pathology report should specify the type of fixation and processing (eg, formalin-fixed paraffin embedded sections), the antibody clone, the general form of detection system used, and the scoring system used (see College of American Pathologists Laboratory Accreditation Program, Anatomic Pathology Checklist, [questions related to reporting of results only, ANP.22988]<sup>48</sup>). Any deviation from the laboratory's standard processing and antigen retrieval protocol should be included. Appropriate positive and negative controls should be used and documented. If normal breast epithelial cells are not immunoreactive for estrogen receptor, the test should be repeated and, if confirmed, this result should be noted. Complete absence of ER positivity for DCIS and normal breast epithelial cells may be due to failure of the assay (eg, failure to apply primary antibody, expired reagent) or loss of immunogenicity of the tissue.

#### **N. Microcalcifications**

Cancer found in biopsies performed for microcalcifications will almost always be at the site of the calcifications or in close proximity.<sup>2,3,5</sup> The presence of the targeted calcifications in the specimen should be confirmed by specimen radiography. The pathologist must be satisfied that the specimen has been sampled in such a way that the

lesion responsible for the calcifications has been examined microscopically. The relationship of the radiologic calcifications to the DCIS should be indicated.

If calcifications are present in the specimen radiograph but not in the initial histologic sections, deeper levels should be examined. If needed, radiographs of the paraffin block(s) may be obtained to detect calcifications remaining in the block(s). If microcalcifications cannot be confirmed by routine microscopic evaluation, polarized light may be helpful to identify calcium oxalate crystals that will polarize but are unstained in H&E sections. On rare occasions, calcifications do not survive tissue processing or prolonged fixation in formalin. Foreign material can sometimes simulate calcifications (eg, metallic fragments after surgery or trauma).

#### **Note O. Clinical Information**

It is a Joint Commission requirement that clinical information be provided for pathology specimens. Relevant clinical information is often necessary for the accurate evaluation of breast specimens and includes:

#### **Patient Information**

Family history of breast or ovarian cancer and/or *BRCA1* or *BRCA2* mutation

Current pregnancy or lactation

Prior breast biopsy or surgery (including implants)

Prior breast cancer diagnosis (type, location in breast, date of diagnosis)

Prior treatment that could affect the breast:

Radiation

Chemotherapy

Hormonal therapy (eg, tamoxifen, aromatase inhibitors, or oral contraceptives)

Systemic diseases that may affect the breast (eg, collagen vascular disease, sarcoidosis, Wegener granulomatosis)

#### **Specimen Information**

Type of lesion sampled:

Palpable mass

Nipple discharge

Nipple lesion (eg, scaling crust)

Imaging finding

Mammographic or ultrasound mass: shape of mass (irregular, circumscribed, ill defined, cystic or solid)

Mammographic calcifications

Mammographic architectural distortion

Prior core needle biopsy site, with or without a clip, with or without residual radiologic or clinical lesion

MRI-detected lesion

Type of specimen:

Excision without wire localization

Excision with wire localization – for these specimens, the specimen radiograph with an interpretation should be available to the pathologist

Nipple duct excision

Total mastectomy

Lymph node specimen (sentinel node, nonsentinel node, limited axillary dissection, complete axillary dissection)

## References

1. Fitzgibbons PL, Connolly JL, Page DL. Protocol for the Examination of Specimens from Patients with Carcinomas of the Breast. In: *Reporting on Cancer Specimens: Case Summaries and Background Documentation*. Northfield, Ill: College of American Pathologists; 2005. Also available at: [http://www.cap.org/apps/cap.portal?\\_nfpb=true&cntvwrPtlit\\_actionOverride=%2Fports%2FcontentViewer%2Fshow&\\_windowLabel=cntvwrPtlit&cntvwrPtlit%7BactionForm.contentReference%7D=committees%2Fcancer%2Fcancer\\_protocols%2Fprotocols\\_index.html&\\_state=maximized&\\_pageLabel=cntvwr](http://www.cap.org/apps/cap.portal?_nfpb=true&cntvwrPtlit_actionOverride=%2Fports%2FcontentViewer%2Fshow&_windowLabel=cntvwrPtlit&cntvwrPtlit%7BactionForm.contentReference%7D=committees%2Fcancer%2Fcancer_protocols%2Fprotocols_index.html&_state=maximized&_pageLabel=cntvwr). Accessed June 18, 2008.
2. Owings DV, Hann L, Schnitt SJ. How thoroughly should needle localization breast biopsies be sampled for microscopic examination? A prospective mammographic/pathologic correlative study. *Am J Surg Pathol*. 1990;14:578-583.
3. Association of Directors of Anatomic and Surgical Pathology. *Recommendations for the Reporting of Breast Carcinoma*. Updated September 2004, Version 1.1. Available at: [www.adasp.org/Checklists/Checklists.htm](http://www.adasp.org/Checklists/Checklists.htm). Accessed June 18, 2008.
4. Schwartz GF, Lagios MD, Carter D, et al. Consensus conference on the classification of ductal carcinoma in situ. *Cancer*. 1997;80:1798-1802.
5. Silverstein MJ, Lagios MD, Recht A, et al. Image-detected breast cancer: state of the art diagnosis and treatment. *J Am Coll Surg*. 2005;201:586-597.
6. Lester SC. *Manual of Surgical Pathology*. 2nd ed. New York: Elsevier; 2006.
7. Silverstein MJ, Poller D, Craig P, et al. A prognostic index for ductal carcinoma in situ of the breast. *Cancer*. 1996;77:2267-2274.
8. Grin A, Horne G, Ennis M, O'Malley FP. Measuring extent of DCIS in breast excision specimens: a comparison of four methods. *Arch Pathol Lab Med*. 2009;133:31-37.
9. Dadmanesh F, Fan X, Dastane A, Amin MB, Bose S. Comparative analysis of size estimation by mapping and counting number of blocks with DCIS in breast excision specimens. *Arch Pathol Lab Med*. 2009;133:26-30.
10. Carlson JW, Birdwell RL, Gombos EC, Golshan M, Smith DN, Lester SC. MRI-directed, wire-localized breast excisions: incidence of malignancy and recommendations for pathologic evaluation. *Hum Pathol*. 2007;38:1754-1759.
11. Vicini FA, Kestin LL, Goldstein NS, Baglan KL, Pettinga JE, Martinez AA. Relationship between excision volume, margin status, and tumor size with the development of local recurrence in patients with ductal carcinoma-in-situ treated with breast-conserving therapy. *J Surg Oncol*. 2001;76:245-254.
12. Lagios MD, Westdahl PR, Margolin FR, et al. Duct carcinoma in situ: relationship of extent of noninvasive disease to the frequency of occult invasion, multicentricity, lymph node metastasis, and short-term treatment failures. *Cancer*. 1982;50:1309-1314.
13. Maffuz A, Barroso-Bravo S, Najera I, Zarco G, Alvarado-Cabrero I, Rogriguez-Cuevas SI. Tumor size as predictor of microinvasion, invasion, and axillary metastasis in ductal carcinoma in situ. *J Exp Clin Cancer Res*. 2006;25:223-227.
14. Moore KH, Sweeney KJ, Wilson ME, et al. Outcomes for women with ductal carcinoma-in-situ and a positive sentinel lymph node: a multi-institutional audit. *Ann Surg Oncol*. 2007;14:2911-2917.
15. Broekhuizen LN, Wijsman JH, Peterse JL, Rutgers EJT. The incidence and significance of micrometastases in lymph nodes of patients with ductal carcinoma in situ and T1a carcinoma of the breast. *Eur J Surg Oncol*. 2006; 32:502-506.
16. Lara JF, Young SM, Velilla RE, Santoro EJ, Templeton SF. The relevance of occult axillary micrometastasis in DCIS: a clinicopathologic study with long-term follow-up. *Cancer*. 2003;98:2105-2113.

17. O'Sullivan MJ, Morrow M. Ductal carcinoma in situ: current management. *Surg Clin North Am.* 2007;87:333-351, viii.
18. Dillon MF, McDermott EW, O'Doherty A, et al. Factors effecting successful breast conservation for ductal carcinoma in situ. *Ann Surg Oncol.* 2007;14:1618-1628.
19. Sigal-Zafrani B, Lewis JS, Clough KB, et al; on behalf of the Institut Curie Breast Study Group. Histologic margin assessment for breast ductal carcinoma in situ: precision and implications. *Mod Pathol.* 2004;17:81-88.
20. Neuschatz AC, DiPetrillo T, Steinhoff M, et al. The value of breast lumpectomy margin assessment as a predictor of residual tumor burden in ductal carcinoma in situ of the breast. *Cancer.* 2002;94:1917-1924.
21. Cheng L, Al-Kaisi NK, Gordon NH, Liu AY, Gebrail F, Shenk RR. Relationship between the size and margin status of ductal carcinoma in situ of the breast and residual disease. *J Natl Cancer Inst.* 1997;89:1356-1360.
22. Di Saverio S, Catena F, Santini D, et al. 259 patients with DCIS of the breast applying USC/Van Nuys prognostic index: a retrospective review with long term follow up. *Breast Cancer Res Treat.* 2008;109:404-416.
23. MacDonald HR, Silverstein MJ, Mabry H, et al. Local control in ductal carcinoma in situ treated by excision alone: incremental benefit of larger margins. *Am J Surg.* 2005;190:521-525.
24. Asjoe FT, Altintas S, Huizing MT, et al. The value of the Van Nuys Prognostic Index in ductal carcinoma in situ of the breast: a retrospective analysis. *Breast J.* 2007;13:359-367.
25. MacDonald HR, Silverstein MJ, Lee LA, et al. Margin width as the sole determinant of local recurrence after breast conservation in patients with ductal carcinoma in situ of the breast. *Am J Surg.* 2006;192:420-422.
26. Saqi A, Osborne MP, Rosenblatt R, Shin SJ, Hoda SA, Quantifying mammary duct carcinoma in situ: a wild-goose chase? *Am J Clin Pathol.* 2000;113(suppl 1):S30-S37.
27. Clingan R, Griffen M, Phillips J, et al. Potential margin distortion in breast tissue by specimen mammography. *Arch Surg.* 2003;138:1371-1374.
28. Graham RA, Homer MJ, Katz J, et al, The pancake phenomenon contributes to the inaccuracy of margin assessment in patients with breast cancer. *Am J Surg.* 2002;184:89-93.
29. Werling RW, Hwang H, Yaziji H, Gown AM, Immunohistochemical distinction of invasive from noninvasive breast lesions: a comparative study of p63 versus calponin and smooth muscle myosin heavy chain. *Am J Surg Pathol.* 2003;27:82-90.
30. Radiation Therapy Oncology Group (RTOG). *Evaluation of Breast Specimens Removed by Needle Localization Technique.* Available at: <http://www.rtog.org/qa/98-04/9804images/9804path1.html>. Accessed June 18, 2008.
31. Torresan RZ, dos Santos CC, Okamura H, Alvarenga M. Evaluation of glandular tissue after skin-sparing mastectomies. *Ann Surg Oncol.* 2005;12:1037-1044.
32. Galow JR, Burstein HJ, Wood W, et al. Preoperative therapy in invasive breast cancer: pathologic assessment and systemic therapy issues in operable disease. *J Clin Oncol.* 2008;26:814-819.
33. Greene FL, Page DL, Fleming ID, et al, eds. *AJCC Cancer Staging Manual.* 6<sup>th</sup> ed. New York: Springer; 2002: 223-240.
34. Connolly JL. Changes and problematic areas in interpretation of the AJCC Cancer Staging Manual, 6<sup>th</sup> Edition, for breast cancer. *Arch Pathol Lab Med.* 2006;130:287-291.

35. Singletary SE, Connolly JL, Breast cancer staging: working with the sixth edition of the AJCC Cancer Staging Manual. *CA Cancer J Clin.* 2006;56:37-47.
36. Singletary SE, Greene FL, Sobin LH. Classification of isolated tumor cells: clarification of the 6<sup>th</sup> edition of the American Joint Committee on Cancer Staging Manual. *Cancer.* 2003;90:2740-2741.
37. Sobin LH, Wittekind C, eds. *UICC TNM Classification of Malignant Tumours.* 6<sup>th</sup> ed. New York, NY: Wiley-Liss; 2002:131-141.
38. Houghton J, George WD, Cuzick J, et al. Radiotherapy and tamoxifen in women with completely excised ductal carcinoma in situ of the breast in the UK, Australia, and New Zealand: randomised controlled trial. *Lancet.* 2003;362:95-103.
39. Fisher B, Land S, Mamounas E, et al, Prevention of invasive breast cancer in women with ductal carcinoma in situ: an update of the National Surgical Adjuvant Breast and Bowel Project Experience. *Semin Oncol.* 2001;28:400-418.
40. Allred D, Bryant J, Land S, et al. Estrogen receptor expression as a predictive marker of the effectiveness of tamoxifen in the treatment of DCIS: findings from NSABP Protocol B-24. *Breast Cancer Res Treat.* 2002;81(suppl 1). Abstract 30.
41. Harris L, Fritsche H, Mennel R, et al. American Society of Clinical Oncology 2007 update of recommendations for the use of tumor markers in breast cancer. *J Clin Oncol.* 2007;25:5287-5312.
42. *NCCN Clinical Practice Guidelines in Oncology. Breast Cancer.* V.2.2008. Fort Washington, Pa: National Comprehensive Cancer Network, Inc; Practice Guidelines in Oncology v.2.2008. Available at: [www.nccn.org/professionals/physician\\_gls/PDF/breast.pdf](http://www.nccn.org/professionals/physician_gls/PDF/breast.pdf). Accessed June 18, 2008.
43. Bradley GG, Schnitt SJ, Collins LC., Ductal carcinoma in situ with basal-like phenotype: a possible precursor to invasive basal-like breast cancer. *Mod Pathol.* 2006;19:617-621.
44. Steinman S, Wang J, Bourne P, et al. Expression of cytokeratin markers, ER-alpha, PR, HER-2/neu, and EGFR in pure ductal carcinoma in situ (DCIS) and DCIS with co-existing invasive ductal carcinoma (IDC) of the breast. *Ann Clin Lab Sci.* 2007;37:127-134.
45. Idval I, Ringberg A, Anderson H, et al. Histopathological and cell biological characteristics of ductal carcinoma in situ (DCIS) of the breast: a comparison between the primary DCIS and subsequent ipsilateral and contralateral tumors. *Breast.* 2005;14:290-297.
46. Bijker N, Pearse JL, Duchateau L, et al. Histological type and marker expression of the primary tumour compared with its local recurrence after breast-conserving therapy for ductal carcinoma in situ. *Br J Cancer.* 2001;84:539-544.
47. Sahoo S, Recant WM, Jaskowiak N, et al. Defining negative margins in DCIS patients treated with breast conservation therapy: the University of Chicago experience. *Breast J.* 2005;11:242-247.
48. Commission on Laboratory Accreditation. Laboratory Accreditation Program. *Anatomic Pathology Checklist.* Northfield, Ill: College of American Pathologists; Sept 2007: Questions Related to Reporting of Results Only. ANP.22988. Available at: [http://www.cap.org/apps/cap.portal?\\_nfpb=true&\\_pageLabel=eLABLAP\\_page](http://www.cap.org/apps/cap.portal?_nfpb=true&_pageLabel=eLABLAP_page). Accessed June 18, 2008.