

Protocol for the Examination of Specimens from Patients with Neuroendocrine Tumors (Carcinoid Tumors) of the Small Intestine and Ampulla

Protocol applies to well-differentiated neuroendocrine tumors of the duodenum, ampulla, jejunum, and ileum. Carcinomas with mixed endocrine/glandular differentiation, poorly differentiated carcinomas with neuroendocrine features, and small cell carcinomas are not included.

Based on AJCC/UICC TNM, 7th Edition

Protocol web posting date: February 2010

Procedures

- Segmental Resection, Small Intestine
- Ampullectomy
- Pancreaticoduodenectomy, Partial or Complete, With or Without Partial Gastrectomy (Whipple Resection)

Authors

Kay Washington, MD, PhD, FCAP*

Department of Pathology, Vanderbilt University Medical Center, Nashville, TN

Laura H. Tang, MD, PhD, FCAP†

Department of Pathology, Memorial Sloan-Kettering Cancer Center, New York, NY

Jordan Berlin, MD

Department of Medicine, Vanderbilt University Medical Center, Nashville, TN

Philip Branton, MD, FCAP

Department of Pathology, Inova Fairfax Hospital, Falls Church, VA

Lawrence J. Burgart, MD, FCAP

Allina Laboratories, Abbott Northwestern Hospital, Minneapolis, MN

David K. Carter, MD, FCAP

Department of Pathology, St. Mary's/Duluth Clinic Health System, Duluth, MN

Carolyn C. Compton, MD, PhD, FCAP†

Office of Biorepositories and Biospecimen Research, National Cancer Institute, Bethesda, MD

Patrick Fitzgibbons, MD, FCAP

Department of Pathology, St. Jude Medical Center, Fullerton, CA

Wendy L. Frankel, MD, FCAP

Department of Pathology, Ohio State University Medical Center, Columbus, OH

John Jessup, MD

Division of Cancer Treatment and Diagnosis, National Cancer Institute, Bethesda, MD

Sanjay Kakar, MD, FCAP

Department of Pathology, University of California San Francisco and the Veterans Affairs Medical Center, San Francisco, CA

Bruce Minsky, MD

Department of Radiation Oncology, University of Chicago, Chicago, IL

Raouf Nakhleh, MD, FCAP

Department of Pathology, Mayo Clinic, Jacksonville, FL

For the Members of the Cancer Committee, College of American Pathologists

*denotes primary author. †denotes secondary author. All other contributing authors are listed alphabetically.

GI • Neuroendocrine Tumors of the Small Intestine and Ampulla
SmallBowelNET 3.0.0.0

© 2010 College of American Pathologists (CAP). All rights reserved.

The College does not permit reproduction of any substantial portion of these protocols without its written authorization. The College hereby authorizes use of these protocols by physicians and other health care providers in reporting on surgical specimens, in teaching, and in carrying out medical research for nonprofit purposes. This authorization does not extend to reproduction or other use of any substantial portion of these protocols for commercial purposes without the written consent of the College.

The CAP also authorizes physicians and other health care practitioners to make modified versions of the Protocols solely for their individual use in reporting on surgical specimens for individual patients, teaching, and carrying out medical research for non-profit purposes.

The CAP further authorizes the following uses by physicians and other health care practitioners, in reporting on surgical specimens for individual patients, in teaching, and in carrying out medical research for non-profit purposes: (1) **Dictation** from the original or modified protocols for the purposes of creating a text-based patient record on paper, or in a word processing document; (2) **Copying** from the original or modified protocols into a text-based patient record on paper, or in a word processing document; (3) The use of a **computerized system** for items (1) and (2), provided that the Protocol data is stored intact as a single text-based document, and is not stored as multiple discrete data fields.

Other than uses (1), (2), and (3) above, the CAP does not authorize any use of the Protocols in electronic medical records systems, pathology informatics systems, cancer registry computer systems, computerized databases, mappings between coding works, or any computerized system without a written license from CAP. Applications for such a license should be addressed to the SNOMED Terminology Solutions division of the CAP.

Any public dissemination of the original or modified Protocols is prohibited without a written license from the CAP.

The College of American Pathologists offers these protocols to assist pathologists in providing clinically useful and relevant information when reporting results of surgical specimen examinations of surgical specimens. The College regards the reporting elements in the "Surgical Pathology Cancer Case Summary (Checklist)" portion of the protocols as essential elements of the pathology report. However, the manner in which these elements are reported is at the discretion of each specific pathologist, taking into account clinician preferences, institutional policies, and individual practice.

The College developed these protocols as an educational tool to assist pathologists in the useful reporting of relevant information. It did not issue the protocols for use in litigation, reimbursement, or other contexts. Nevertheless, the College recognizes that the protocols might be used by hospitals, attorneys, payers, and others. Indeed, effective January 1, 2004, the Commission on Cancer of the American College of Surgeons mandated the use of the checklist elements of the protocols as part of its Cancer Program Standards for Approved Cancer Programs. Therefore, it becomes even more important for pathologists to familiarize themselves with these documents. At the same time, the College cautions that use of the protocols other than for their intended educational purpose may involve additional considerations that are beyond the scope of this document.

The inclusion of a product name or service in a CAP publication should not be construed as an endorsement of such product or service, nor is failure to include the name of a product or service to be construed as disapproval.

CAP Small Bowel NET Protocol Revision History

Version Code

The definition of the version code can be found at www.cap.org/cancerprotocols.

Version: SmallBowelNET 3.0.0.0

Summary of Changes

No changes have been made since the October 2009 release.

Surgical Pathology Cancer Case Summary (Checklist)

Protocol web posting date: February 2010

SMALL INTESTINE AND AMPULLA: Segmental Resection, Ampullectomy, Pancreaticoduodenectomy (Whipple Resection)

Select a single response unless otherwise indicated.

Specimen (select all that apply) (Note A)

- Duodenum
 Ampulla of Vater
 Small intestine
 * Jejunum
 * Ileum
 * Unknown

Other organs received:

- Stomach
 Head of pancreas
 Common bile duct
 Gallbladder
 Cecum
 Right colon
 Appendix
 Other (specify): _____
 Not specified

Procedure

- Segmental resection
 Ampullectomy
 Pancreaticoduodenectomy (Whipple resection)
 Other (specify): _____
 Not specified

***Specimen Size (if applicable)**

*Specify: ___ (length) x ___ x ___ cm

Tumor Site (select all that apply) (Note B)

- Duodenum
 Ampulla
 Small bowel
 * Jejunum
 * Ileum
 Other (specify): _____
 Not specified

* Data elements with asterisks are not required. However, these elements may be clinically important but are not yet validated or regularly used in patient management.

Tumor Size (Note C)

Greatest dimension: ___ cm (specify size of largest tumor if multiple tumors are present)

*Additional dimensions: ___ x ___ cm

___ Cannot be determined (see "Comment")

Tumor Focality

___ Unifocal

___ Multifocal (specify number of tumors: _____)

___ Cannot be determined

Histologic Type (Note D)

___ Carcinoid tumor (low-grade neuroendocrine neoplasm)

* ___ Somatostatinoma

* ___ Gastrinoma

* ___ Gangliocytic paraganglioma

* ___ Other (specify): _____

***Alternative Histologic Classification (Note D)**

* ___ Well-differentiated endocrine tumor, benign behavior

* ___ Well-differentiated endocrine tumor, uncertain behavior

* ___ Well-differentiated endocrine carcinoma

Histologic Grade (Note E)[#]

___ Not applicable

___ GX: Cannot be assessed

___ G1: Low grade

___ G2: Intermediate grade

___ Other (specify): _____

[#] For poorly differentiated neuroendocrine carcinomas arising in the small intestine or ampulla, the College of American Pathologists (CAP) checklists for carcinomas of those organ sites should be used.^{1,2}

Mitotic Rate

Specify: ___/10 high-power fields (HPF)

___ Cannot be determined

Microscopic Tumor Extension: Small Intestine

___ Cannot be assessed

___ No evidence of primary tumor

___ Tumor invades lamina propria

___ Tumor invades submucosa

___ Tumor invades muscularis propria

___ Tumor invades subserosal tissue without involvement of visceral peritoneum

___ Tumor penetrates serosa (visceral peritoneum)

___ Tumor directly invades adjacent structures (specify: _____)

___ Tumor penetrates to the surface of the visceral peritoneum (serosa) and directly invades adjacent structures (specify: _____)

* Data elements with asterisks are not required. However, these elements may be clinically important but are not yet validated or regularly used in patient management.

Microscopic Tumor Extension: Ampulla

- Cannot be assessed
 No evidence of primary tumor
 Tumor limited to ampulla of Vater or sphincter of Oddi
 Tumor invades duodenal wall
 Tumor invades pancreas
 Tumor invades peripancreatic soft tissues
 Tumor invades common bile duct
 Tumor invades other adjacent organs or structures (specify): _____

MarginsSmall Intestine Resection Specimen*Proximal Margin*

- Cannot be assessed
 Uninvolved by neuroendocrine tumor
 Involved by neuroendocrine tumor

Distal Margin

- Cannot be assessed
 Uninvolved by neuroendocrine tumor
 Involved by neuroendocrine tumor

Mesenteric (Radial) Margin (Note F)

- Cannot be assessed
 Uninvolved by neuroendocrine tumor
 Involved by neuroendocrine tumor

Other Margin(s) (specify): _____

- Not applicable
 Cannot be assessed
 Uninvolved by neuroendocrine tumor
 Involved by neuroendocrine tumor

Ampullectomy Specimen

- Margins cannot be assessed
 Margins uninvolved by neuroendocrine tumor
 Distance of neuroendocrine tumor from closest margin: ___ mm or ___ cm
 Specify margin (if possible): _____
 Margin(s) involved by neuroendocrine tumor
 Specify margin(s) (if possible): _____
 Not applicable

Pancreaticoduodenal Resection Specimen (for ampullary tumors)*Proximal Mucosal Margin (Gastric or Duodenal)*

- Cannot be assessed
 Uninvolved neuroendocrine tumor
 Involved by neuroendocrine tumor

* Data elements with asterisks are not required. However, these elements may be clinically important but are not yet validated or regularly used in patient management.

Distal Margin (Distal Duodenal or Jejunal)

- Cannot be assessed
 Uninvolved by neuroendocrine tumor
 Involved by neuroendocrine tumor

Pancreatic Retroperitoneal (Uncinate) Margin

- Not applicable
 Cannot be assessed
 Uninvolved by neuroendocrine tumor
 Involved by neuroendocrine tumor (present 0-1 mm from margin)

Bile Duct Margin

- Not applicable
 Cannot be assessed
 Margin uninvolved by neuroendocrine tumor
 Margin involved by neuroendocrine tumor

Distal Pancreatic Resection Margin

- Not applicable
 Cannot be assessed
 Margin uninvolved by neuroendocrine tumor
 Margin involved by neuroendocrine tumor

If all margins uninvolved by neuroendocrine tumor:

Distance of tumor from closest margin: ___ mm or ___ cm

Specify margin: _____

Lymph-Vascular Invasion

- Not identified
 Present
 Indeterminate

***Perineural Invasion**

- Not identified
 Present
 Indeterminate

Pathologic Staging (pTNM) (Note G)

TNM Descriptors (required only if applicable) (select all that apply)

- m (multiple primary tumors)
 r (recurrent)
 y (posttreatment)

* Data elements with asterisks are not required. However, these elements may be clinically important but are not yet validated or regularly used in patient management.

Primary Tumor (pT)

- pTX: Primary tumor cannot be assessed
- pT0: No evidence of primary tumor
- pT1: Tumor invades lamina propria or submucosa and size 1 cm or less (small intestinal tumors); tumor 1 cm or less (ampullary tumors)
- pT2: Tumor invades muscularis propria or tumor size >1 cm (small intestinal tumors); tumor size >1 cm (ampullary tumors)
- pT3: Tumor invades through the muscularis propria into subserosal tissue without penetration of overlying serosa (jejunal or ileal tumors) or invades pancreas or retroperitoneum (ampullary or duodenal tumors) or into nonperitonealized tissues
- pT4: Tumor penetrates visceral peritoneum (serosa) or invades other organs

Regional Lymph Nodes (pN)

- Cannot be assessed
- pN0: No regional lymph node metastasis
- pN1: Metastasis in regional lymph nodes
- Specify: Number examined: ____
- Number involved: ____

Distant Metastasis (pM)

- Not applicable
- pM1: Distant metastasis
- *Specify site(s), if known: _____

***Ancillary Studies (select all that apply) (Note H)**

- * Ki-67 index
- * ≤2%
- * >2% to 20%
- * >20%
- * Other (specify): _____
- * Not performed

***Additional Pathologic Findings (select all that apply) (Note I)**

- * Endocrine cell hyperplasia
- * Tumor necrosis
- * Psammoma bodies
- * Mesenteric vascular elastosis
- * Other (specify): _____

***Comment(s)**

* Data elements with asterisks are not required. However, these elements may be clinically important but are not yet validated or regularly used in patient management.

Explanatory Notes

A. Application and Tumor Location

This protocol applies to well-differentiated neuroendocrine neoplasms (carcinoid tumors) of the small intestine and ampulla of Vater. Poorly differentiated neuroendocrine carcinomas, small cell carcinomas, and tumors with mixed glandular/neuroendocrine differentiation are not included.

Because of site-specific similarities in histology, immunohistochemistry, and histochemistry, neuroendocrine tumors of the digestive tract have traditionally been subdivided into those of foregut, midgut, and hindgut origin (Table). In general, the distribution pattern along the gastrointestinal (GI) tract parallels that of the progenitor cell type, and the anatomic site of origin of GI neuroendocrine tumors is an important predictor of clinical behavior.³

Site of Origin of Gastrointestinal Neuroendocrine Tumors

	Foregut Tumors	Midgut Tumors	Hindgut Tumors
<i>Site</i>	<i>Stomach, Proximal Duodenum</i>	<i>Jejunum, Ileum, Appendix, Proximal Colon</i>	<i>Distal Colon, Rectum</i>
Immunohistochemistry			
Chromogranin A	86%-100% +	82%-92% +	40%-58% +
Neuron-Specific Enolase (NSE)	90%-100% +	95%-100% +	80%-87% +
Synaptophysin	50% +	95%-100% +	94%-100% +
Serotonin	33% + ^{16,17}	86% + ^{16,17}	45%-83% + ^{4-6,17}
Other Immunohistochemical Markers	Rarely, + for pancreatic polypeptide, histamine, gastrin, vasoactive intestinal peptide (VIP), or adrenocorticotrophic hormone (ACTH)	Prostatic acid phosphatase + in 20%-40% ^{16,17}	Prostatic acid phosphatase + in 20%-82% ^{4-6,17}
Carcinoid Syndrome	Rare	5%-39% ^{7,8}	Rare

B. Site Specific Features

Duodenal NETs are relatively uncommon, accounting for roughly 4% of GI NETs.⁴ The most common subtype is the gastrin-secreting NET, or gastrinoma, associated with Zollinger-Ellison syndrome in one-third of cases.⁵ These gastrin-secreting tumors are often associated with multiple endocrine neoplasia type 1 (MEN1) syndrome, but sporadic tumors also occur.⁶ Duodenal somatostatin-producing tumors (somatostatinomas) are less common, accounting for about 1% of GI NETs, and are seldom associated with the functional syndrome of mild diabetes mellitus, cholelithiasis, and steatorrhea. These tumors often have a pure glandular growth pattern with scattered psammoma bodies and may be confused with conventional adenocarcinomas.⁷ They arise almost exclusively in the ampulla or periampullary duodenum and are often associated with MEN1 and with neurofibromatosis type 1.⁸

Most small bowel neuroendocrine tumors occur in the distal ileum. Multiple tumors are found in 25% to 40% of cases and may be associated with a worse outcome.⁹ Metastatic

risk is increased by tumor size >2 cm, involvement of the muscularis propria, and mitotic activity.³

C. Tumor Size

For neuroendocrine tumors in any part of the gastrointestinal tract, size greater than 2.0 cm is associated with a higher risk of lymph node metastasis. For jejunoileal tumors, nodal metastases occur in about 12% of patients with tumors smaller than 1.0 cm and in most patients with tumors larger than 1.0 cm.³ Thus, treatment for small bowel carcinoid tumor includes complete resection with regional lymphadenectomy.

D. Histologic Type

The World Health Organization (WHO) classifies neuroendocrine neoplasms as well-differentiated neuroendocrine tumors, well-differentiated neuroendocrine carcinomas, and poorly differentiated neuroendocrine carcinomas.^{5,7,10} Historically, well-differentiated neuroendocrine neoplasms have been referred to as carcinoid tumors, a term which may cause confusion because clinically a carcinoid tumor is a serotonin-producing tumor associated with functional manifestations of carcinoid syndrome.

Classification of neuroendocrine tumors is based upon size, functionality, site, and invasion. Functioning tumors are those associated with clinical manifestations of hormone production or secretion of measurable amounts of active hormone; immunohistochemical demonstration of hormone production is not equivalent to clinically apparent functionality.

Neuroendocrine Tumors of the Small Bowel

Well-Differentiated Neuroendocrine Tumor

Benign: Nonfunctioning cytologically bland tumors confined to mucosa or submucosa, with no angioinvasion, and measuring not more than 1 cm in greatest dimension.

Uncertain malignant potential: Nonfunctioning cytologically bland tumors confined to mucosa or submucosa, with or without angioinvasion, or greater than 1 cm in size.

All gangliocytic paragangliomas without metastases are included in this category.

Well-differentiated Neuroendocrine Carcinoma

Low-grade malignant potential: Nonfunctioning tumors that are larger than 2 cm or invade the muscularis propria or beyond or are metastatic. All functional tumors, such as small gastrinomas, are included in this category

Histologic Patterns

Although specific histologic patterns in well-differentiated neuroendocrine neoplasms, such as trabecular, insular, and glandular, roughly correlate with tumor location,¹¹ these patterns have not been clearly shown independently to predict response to therapy or risk of nodal metastasis and are rarely reported in clinical practice.

E. Histologic Grade

Cytologic atypia in low-grade neuroendocrine tumors has no impact on clinical behavior of these tumors. However, grading systems based on mitotic activity have been shown to have utility for foregut tumors. The following grading system is recommended¹²:

Grade	Mitotic Count (per 10 HPF) #	Ki-67 Index (%)##
G1	<2	≤2
G2	2 to 20	>2 to 20
G3	>20	>20

Mitotic count should be based upon counting 50 high-power (40x objective) fields in the area of highest mitotic activity and reported as number of mitoses per 10 HPF.

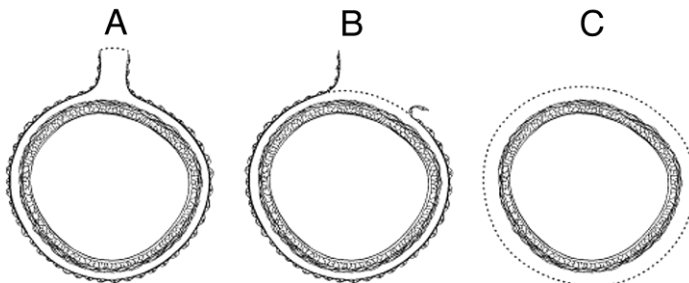
Ki-67 index is reported as percentage of positive tumor cells in area of highest nuclear labeling. It has been recommended that 2000 tumor cells be counted to determine the Ki-67 index¹²; however, this practice may not be practical for routine clinical purposes, and it is acceptable to estimate the labeling index.

G1 and G2 are well-differentiated tumors with diffuse intense chromogranin/synaptophysin positivity. Punctate necrosis is more typical of G2 tumors. G3 tumors are high-grade neuroendocrine carcinomas (the CAP carcinoma checklist for the appropriate organ system should be used for poorly differentiated neuroendocrine carcinomas of the small intestine¹ and ampulla²).

F. Circumferential (Radial or Mesenteric) Margin

In addition to addressing the proximal and distal margins, assessment of the circumferential (radial) margin is necessary for any segment of gastrointestinal tract either unencased (Figure, C) or incompletely encased by peritoneum (Figure, B). The circumferential margin represents the adventitial soft tissue margin closest to the deepest penetration of tumor and is created surgically by blunt or sharp dissection of the retroperitoneal or subperitoneal aspect, respectively. The distance between the tumor and circumferential (radial) margin should be reported. The circumferential (radial) margin is considered negative if the tumor is more than 1 mm from the inked nonperitonealized surface but should be recorded as positive if tumor is located 1 mm or less from the nonperitonealized surface. This assessment includes tumor within a lymph node as well as direct tumor extension, but if circumferential (radial) margin positivity is based solely on intranodal tumor, this should be so stated.

The mesenteric resection margin is the only relevant circumferential margin in segments completely encased by peritoneum (eg, jejunum and ileum) (Figure 1, A). Involvement of this margin should be reported even if tumor does not penetrate the serosal surface.



A, Mesenteric margin in viscus completely encased by peritoneum (dotted line).

B, Circumferential (radial) margin (dotted line) in viscus incompletely encased by peritoneum.

C, Circumferential (radial) margin (dotted line) in viscus completely unencased by peritoneum.

Reproduced with permission from Washington et al.¹⁸ Copyright 2008. College of American Pathologists.

G. TNM and Stage Groupings

The TNM staging system for neuroendocrine tumors of the duodenum, ampulla, and small bowel of the American Joint Committee on Cancer (AJCC) and the International Union Against Cancer (UICC) is recommended.¹³

By AJCC/UICC convention, the designation “T” refers to a primary tumor that has not been previously treated. The symbol “p” refers to the pathologic classification of the TNM, as opposed to the clinical classification, and is based on gross and microscopic examination. pT entails a resection of the primary tumor or biopsy adequate to evaluate the highest pT category, pN entails removal of nodes adequate to validate lymph node metastasis, and pM implies microscopic examination of distant lesions. Clinical classification (cTNM) is usually carried out by the referring physician before treatment during initial evaluation of the patient or when pathologic classification is not possible.

Pathologic staging is usually performed after surgical resection of the primary tumor. Pathologic staging depends on pathologic documentation of the anatomic extent of disease, whether or not the primary tumor has been completely removed. If a biopsied tumor is not resected for any reason (eg, when technically unfeasible) and if the highest T and N categories or the M1 category of the tumor can be confirmed microscopically, the criteria for pathologic classification and staging have been satisfied without total removal of the primary cancer.

TNM Descriptors

For identification of special cases of TNM or pTNM classifications, the “m” suffix and “y,” “r,” and “a” prefixes are used. Although they do not affect the stage grouping, they indicate cases needing separate analysis.

The “m” suffix indicates the presence of multiple primary tumors in a single site and is recorded in parentheses: pT(m)NM.

The “y” prefix indicates those cases in which classification is performed during or following initial multimodality therapy (ie, neoadjuvant chemotherapy, radiation therapy, or both chemotherapy and radiation therapy). The cTNM or pTNM category is identified by a “y” prefix. The ycTNM or ypTNM categorizes the extent of tumor actually present at the time of that examination. The “y” categorization is not an estimate of tumor prior to multimodality therapy (ie, before initiation of neoadjuvant therapy).

The “r” prefix indicates a recurrent tumor when staged after a documented disease-free interval, and is identified by the “r” prefix: rTNM.

The “a” prefix designates the stage determined at autopsy: aTNM.

N Category Considerations

The regional lymph nodes for the small intestine vary with site. For duodenal tumors, the regional lymph nodes are duodenal, hepatic, pancreaticoduodenal, infrapyloric, gastroduodenal, pyloric, superior mesenteric, and pericholedochal nodes. For ileal and jejunal tumors, the regional lymph nodes are the cecal (for tumors arising in the terminal ileum), superior mesenteric, and mesenteric nodes. Metastases to celiac nodes are considered distant metastases.

The regional nodes for the ampulla may be subdivided as follows:

Superior: Lymph nodes superior to head and body of pancreas

Inferior: Lymph nodes inferior to head and body of pancreas

Anterior: Anterior pancreaticoduodenal, pyloric, and proximal mesenteric lymph nodes

Posterior: Posterior pancreaticoduodenal, common bile duct or pericholedochal, and proximal mesenteric nodes

TNM Anatomic Stage/Prognostic Groupings

Stage I	T1	N0	M0 [#]
Stage IIa	T2	N0	M0
Stage IIb	T3	N0	M0
Stage IIIa	T4	N0	M0
Stage IIIb	Any T	N1	M0
Stage IV	Any T	Any N	M1

[#] M0 is defined as no distant metastasis.

H. Ancillary Studies

Immunohistochemistry and other ancillary techniques are generally not required to diagnose well-differentiated neuroendocrine tumors. Specific markers that may be used to establish neuroendocrine differentiation include chromogranin A, neuron-specific enolase, synaptophysin, and CD56.⁷ Because of their relative sensitivity and specificity, chromogranin A and synaptophysin are recommended.

Immunohistochemistry for Ki-67 may be useful in establishing tumor grade (Note E) and prognosis¹² but is not currently considered standard of care.⁷

Immunohistochemistry for specific hormone products, such as glucagon, gastrin, and somatostatin, may be of interest in some cases. However, immunohistochemical demonstration of hormone production does not equate with clinical functionality of the tumor.

I. Additional Pathologic Findings

Psammoma bodies are commonly found in duodenal neuroendocrine tumors, especially periampullary tumors¹⁴ expressing somatostatin and associated with von Recklinghausen disease.⁵

Mesenteric vascular changes (elastic vascular sclerosis) associated with midgut carcinoids may produce arterial luminal narrowing due to concentric accumulation of elastic tissue in the adventitia. These vascular changes may lead to intestinal ischemia and frank necrosis.¹⁵

References

1. Washington K, Berlin J, Branton P, et al. Protocol for the examination of specimens from patients with carcinoma of the small intestine. In: *Reporting on Cancer Specimens: Case Summaries and Background Documentation*. Northfield, IL: College of American Pathologists; 2009.
2. Washington K, Berlin J, Branton P, et al. Protocol for the examination of specimens from patients with carcinoma of the ampulla of Vater. In: *Reporting on Cancer Specimens: Case Summaries and Background Documentation*. Northfield, IL: College of American Pathologists; 2009.

3. Rorstad O. Prognostic indicators for carcinoid neuroendocrine tumors of the gastrointestinal tract. *J Surg Oncol*. 2005;89(3):151-160.
4. Modlin IM, Lye KD, Kidd M. A 5-decade analysis of 13,715 carcinoid tumors. *Cancer*. 2003;97(4):934-959.
5. Graeme-Cook F. Neuroendocrine tumors of the GI tract and appendix. In: Odze RD, Goldblum JR, Crawford JM, eds. *Surgical Pathology of the GI Tract, Liver, Biliary Tract, and Pancreas*. Philadelphia, PA: Saunders; 2004: 483-504.
6. Anlauf M, Garbrecht N, Henopp T, et al. Sporadic versus hereditary gastrinomas of the duodenum and pancreas: distinct clinico-pathological and epidemiological features. *World J Gastroenterol*. 2006;12(34):5440-5446.
7. Williams GT. Endocrine tumours of the gastrointestinal tract: selected topics. *Histopathology*. 2007;50(1):30-41.
8. Garbrecht N, Anlauf M, Schmitt A, et al. Somatostatin-producing neuroendocrine tumors of the duodenum and pancreas: incidence, types, biological behavior, association with inherited syndromes, and functional activity. *Endocr Rel Cancer*. 2008;15(1):229-241.
9. Yantiss RK, Odze RD, Farraye FA, Rosenberg AE. Solitary versus multiple carcinoid tumors of the ileum: a clinical and pathologic review of 69 cases. *Am J Surg Pathol*. 2003;27(6):811-817.
10. Kloppel G, Perren A, Heitz PU. The gastroenteropancreatic neuroendocrine cell system and its tumors: the WHO classification. *Ann N Y Acad Sci*. 2004;1014:13-27.
11. Soga J. Carcinoids of the colon and ileocecal region: a statistical evaluation of 363 cases collected from the literature. *J Exp Clin Cancer Res*. 1998;17(2):139-148.
12. Rindi G, Kloppel G, Alhman H, et al; and all other Frascati Consensus Conference participants; European Neuroendocrine Tumor Society (ENETS). TNM staging of foregut (neuro)endocrine tumors: a consensus proposal including a grading system. *Virchows Arch*. 2006;449(4):395-401.
13. Edge SB, Byrd DR, Carducci MA, Compton CC, eds. *AJCC Cancer Staging Manual*. 7th ed. New York, NY: Springer; 2009.
14. Burke AP, Sobin LH, Federspiel BH, ShekiTkta KM, Helwig EB. Carcinoid tumors of the duodenum: a clinicopathologic study of 99 cases. *Arch Pathol Lab Med*. 1990;114(7):700-704.
15. Eckhauser FE, Argenta LC, Strodel WE, et al. Mesenteric angiopathy, intestinal gangrene, and midgut carcinoids. *Surgery*. 1981;90(4):720-728.
16. Kimura N, Sasano N. Prostate-specific acid phosphatase in carcinoid tumors. *Virchows Arch A Pathol Anat Histopathol*. 1986;410(3):247-251.
17. Nash SV, Said JW. Gastroenteropancreatic neuroendocrine tumors: a histochemical and immunohistochemical study of epithelial (keratin proteins, carcinoembryonic antigen) and neuroendocrine (neuron-specific enolase, bombesin and chromogranin) markers in foregut, midgut, and hindgut tumors. *Am J Clin Pathol*. 1986;86(2):415-422.
18. Washington MK, Berlin J, Branton PA, et al. Protocol for the examination of specimens from patients with primary carcinomas of the colon and rectum. *Arch Pathol Lab Med*. 2008;132(7):1182-1193.